

Case Reports

## Long-Segment Stricture After Systemic Thrombolysis in a Full-Term Infant with Intestinal Ischemia due to Midgut Volvulus



Katherine Carlton<sup>2</sup>, Amanda B. Witte<sup>1</sup>, Katherine T. Flynn-O'Brien<sup>1</sup>, Girija G. Konduri<sup>2</sup>, Dave R. Lal<sup>1</sup>, Kyle J. Van Arendonk<sup>1</sup> and Caroline Maloney<sup>1</sup>

<sup>1</sup>Division of Pediatric Surgery, Department of Surgery, <sup>2</sup>Division of Neonatology, Department of Pediatrics, Medical College of Wisconsin, Children's Wisconsin, Milwaukee, Wisconsin.

### ABSTRACT

**Background:** Midgut volvulus secondary to congenital intestinal malrotation is a neonatal surgical emergency that can quickly progress to intestinal ischemia. Even following timely relief of volvulus and the associated vascular obstruction, persistent thrombosis of mesenteric vessels can lead to extensive intestinal necrosis. Published cases have described the successful use of systemic thrombolysis to treat mesenteric vessel thrombosis following resolution of volvulus; however, the long-term intestinal function after salvage with thrombolysis remains underreported.

**Case Presentation:** We present a case of a two-day old term infant who presented with malrotation and midgut volvulus, with resultant near total intestinal ischemia on initial operation. Systemic tissue-type plasminogen activator (tPA) was administered for 48 hours with dramatic improvement in ischemia and salvage of nearly 150cm of intestinal length. Post-operatively, the patient was unable to tolerate enteral nutrition, and upon re-operation at 7 weeks was found to have multiple long intestinal strictures. Following resection of small bowel strictures, the infant was left with 47cm of small bowel and subsequently underwent a serial transverse enteroplasty procedure (STEP), allowing the infant to tolerate partial enteral feeds.

**Conclusion:** Post-operative use of systemic thrombolysis has shown promise in the reversal of intestinal ischemia following midgut volvulus; however, the outcomes are variable and underreported in the current literature. We describe a case of post-operative thrombolysis resulting in initial intestinal salvage but with development of significant strictures requiring additional intestinal resection. Understanding the potential successes and complications of thrombolysis can improve the care provided to neonates with mesenteric ischemia after midgut volvulus.

**Keywords:** Case report; intestinal ischemia; midgut volvulus; short bowel syndrome ; thrombolysis.

**How to Cite:** Katherine Carlton, Amanda B. Witte, Katherine T. Flynn-O'Brien, Girija G. Konduri, Dave R. Lal, Kyle J. Van Arendonk and Caroline Maloney.: Long-Segment Stricture After Systemic Thrombolysis in a Full-Term Infant with Intestinal Ischemia due to Midgut Volvulus. *Ann Pediatr Surg*. 2024; 20:4, 1-5. DOI: 10.21608/APSJ.2024.251681.1023

### BACKGROUND

Intestinal malrotation is a congenital anomaly that occurs due to failure of normal rotation and fixation, allowing the small bowel to rotate around its mesentery leading to midgut volvulus [1, 2]. Sixty to eighty percent of volvulus occurs in

Received: 31 August 2024, Accepted: 31 August 2024

Corresponding Author: Katherine Carlton, Department of Pediatrics, Division of Neonatology, Children's Corporate Center, 999 N. 92nd Street, Suite C410, Milwaukee, WI 53226, Tel.: 414-266-6820, E-mail: kcarlton@mcw.edu.

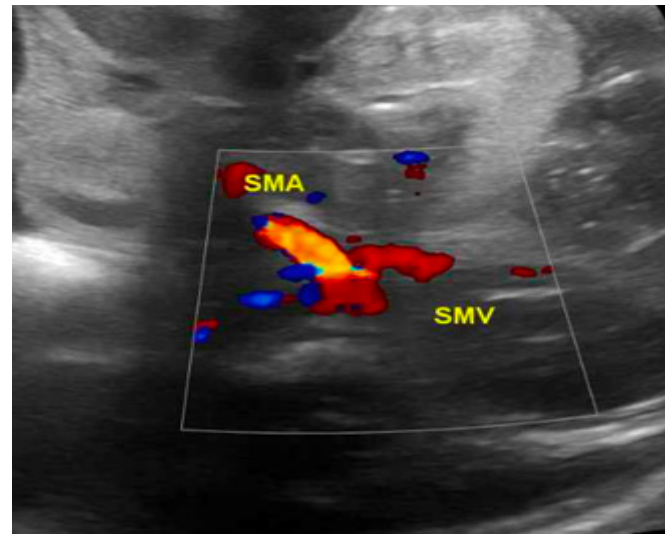
ISSN: 2090-0740, 2024

the first month of life, and standard treatment involves de-rotation of the intestines with a Ladd's procedure<sup>[3]</sup>. However, timely de-rotation does not always restore intestinal blood supply adequately, and the resulting intestinal infarction from persistent thrombosis of the mesenteric vessels may necessitate extensive small bowel resection<sup>[4]</sup>. Depending on the length and location of the remaining shortened bowel, patients who survive may suffer from parenteral nutrition dependence, secondary liver disease, catheter-induced bloodstream infections, prolonged periods of hospitalization, and mortality<sup>[4, 5]</sup>. For the approximately 15% of patients who present with intestinal ischemia as a result of midgut volvulus, systemic thrombolysis has been proposed based on the management of mesenteric ischemia reported in adult populations<sup>[2]</sup>. Two case reports have described using a continuous infusion of tissue-type plasminogen activator (tPA) in neonates with midgut volvulus and resultant intestinal ischemia. A tPA infusion is started during the post-operative period to promote mesenteric thrombolysis and restore blood flow, with the potential to reverse the severe intestinal ischemia noted during laparotomy<sup>[1, 2]</sup>. All neonates in the case reports survived with limited small bowel resection, allowing enteral feeding autonomy at discharge. The following case describes a full-term infant who presented with midgut volvulus and was found at laparotomy to have diffuse small bowel ischemia. After completion of a Ladd's procedure, post-operative systemic thrombolysis resulted in initial bowel salvage, but was subsequently complicated by the development of a long-segment intestinal stricture requiring multiple bowel resections and eventually a serial transverse enteroplasty procedure (STEP). This manuscript was prepared according to the CARE guidelines for case reports<sup>[6]</sup>.

## CASE PRESENTATION

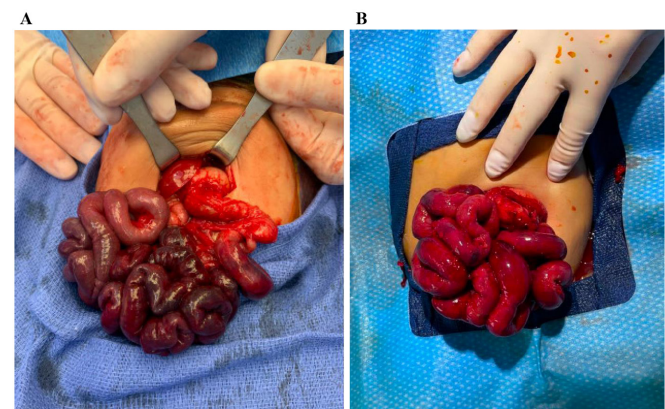
A two-day old infant born at 39-weeks gestation via repeat cesarean section developed respiratory distress in the delivery room requiring intubation and neonatal intensive care unit (NICU) admission at an outside facility. At 48 hours of life, after clinical improvement from a respiratory perspective, the infant acutely developed abdominal distension despite a lack of enteral feeding. Hemocult-positive, bilious output was noted in the orogastric tube, and an abdominal x-ray showed decreased bowel gas diffusely without signs of pneumatosis or free air. Laboratory evaluation identified an acute drop in hematocrit from 43% to 22% since NICU admission. Central venous access was obtained. The infant was transferred to our facility where an immediate bedside abdominal ultrasound showed an inverted superior mesenteric artery-vein relationship with a whirl sign, indicating a midgut volvulus

(Figure 1).



**Fig. 1:** Bowel ultrasound on day of life 2. Bowel ultrasound demonstrating the inverted superior mesenteric artery-vein relationship with swirl sign, indicating the presence of a midgut volvulus.

The infant was emergently taken to the operating room for an exploratory laparotomy, where a midgut volvulus with four 180-degree turns was confirmed. Diffusely thrombosed mesenteric vessels and a narrowed mesentery were noted. 170 cm of small bowel was markedly ischemic with only the most proximal 10 cm of small bowel and the colon appearing well-perfused (Figure 2). After completion of the Ladd's procedure, the appearance of the bowel did not improve. Therefore, the intestines were placed in a 7.5 cm spring-loaded silo, and the infant was returned to the NICU with plans for a second look laparotomy.



**Fig. 2:** Small bowel before and after thrombolysis. (A) Initial exploratory laparotomy performed on day 2 of life demonstrated midgut volvulus with diffusely thrombosed mesentery and 170 cm of markedly ischemic small bowel. (B) Second-look laparotomy (day 6 of life) after discontinuation of tPA showed 149 cm of small bowel without obvious ischemia.

The neonatology and pediatric surgery teams relayed a guarded prognosis to the family given the significant amount of bowel ischemia and high risk for short bowel syndrome in the future. Systemic thrombolysis with continuous tPA infusion was proposed as a method of intestinal salvage, and the family was agreeable. Therefore, the decision was made to proceed with systemic thrombolysis in consultation with a pediatric hematologist. The infant remained sedated and was kept on broad spectrum antibiotics.

Post-operative fluid resuscitation was performed, and baseline laboratory assessment including complete blood count, coagulation studies, and type and screen for blood products were obtained to ensure fibrinogen >100 mg/dl and platelets >100,000/ $\mu$ l. A baseline cranial ultrasound was negative for intraventricular hemorrhage. At five hours post-operatively, tPA infusion was initiated at 0.2 mg/kg/hr along with a low-dose heparin infusion at 5 units/kg/hr. Complete blood count and coagulation studies were monitored every 2 hours, and packed red blood cell, platelet, and fresh frozen plasma transfusions were given as necessary to replace losses from the silo and to maintain platelets >100,000/ $\mu$ l and fibrinogen >100 mg/dl. After 6 hours of tPA infusion and 120 mg/kg of blood product transfusion, bedside silo removal showed improved but patchy intestinal perfusion. The tPA was restarted at a lowered dose of 0.05 mg/kg/hr and continued for an additional 24 hours (30 hours on tPA total). After tPA was discontinued, abdominal exploration showed 149 cm of viable-appearing bowel with improved perfusion. There were two small areas of jejunum with full-thickness necrosis that were resected, totaling 10 cm in length (Figure 2B), and intestinal continuity was reestablished with two handsewn bowel anastomoses. A gastrostomy tube was placed given the likelihood of short bowel syndrome and need for long-term continuous drip feeding. The abdomen was then closed, and the low-dose heparin infusion was discontinued.

Post-operatively the patient was supported with parenteral nutrition while waiting for return of bowel function. The patient was extubated 48 hours after her second-look laparotomy (day 8 of life). She remained on full parenteral nutrition due to emesis with even small amounts of feeds. An upper GI contrast study with small bowel follow-through performed on post-operative day 15 showed opacification of the proximal small bowel loops without contrast passage beyond the proximal small intestine. The same findings were again demonstrated on a repeat UGI series on post-operative day 31, raising concern for intestinal stricture.

On post-operative day 53 (day 59 of life), exploratory laparotomy was performed with extensive lysis of adhesions. There was a clear area of transition from dilated jejunum to narrowed jejunum/ileum. An enterotomy was created, and a 6 Fr Foley catheter was used to assess for a stricture. One centimeter from the enterotomy a luminal stricture was encountered. The bowel distal to this was opened, and again resistance was met when inserting the catheter. With progressive inspection in this fashion, much of the intervening

bowel between the dilated jejunum and terminal ileum was found to have complete luminal obstruction. Examination of the mucosa also demonstrated that it was fibrotic, pale, and scarred. The colon was flushed retrograde with saline through a red rubber catheter placed transanally, and the colon was found to be patent to the cecum. The patient underwent an extensive resection of the strictured small bowel, leaving 50 cm of viable small bowel with a single anastomosis at the terminal ileum.

The patient returned to the NICU in stable condition and was maintained on total parenteral nutrition (TPN). However, she developed a second stricture at the anastomosis approximately one month later. She also developed signs of TPN-induced cholestasis with an elevated conjugated bilirubin to 7.7 mg/dL. This prompted another operative exploration, revealing a short segment stricture at the ileocecal anastomosis. The proximal bowel was significantly dilated and grossly patent. A 3 cm resection of her stricture with cecectomy and primary ileocolonic anastomosis was performed, removing the ileocecal valve. Her remaining small bowel length was 47 cm. As the remaining small bowel was significantly dilated to 4-5 cm, a STEP was performed to improve functional bowel surface area, using ten firings of the stapler with 1.5 cm spacing along the bowel. The patient tolerated the procedure well and was taken to the NICU extubated in stable condition. She recovered from the STEP procedure uneventfully and was discharged home on TPN with small volume feeds via gastrostomy tube. At follow-up at 12 months of age, the child is tolerating 40 mL/kg/day of enteral feeds with supplemental TPN.

## DISCUSSION

Severe intestinal ischemia from midgut volvulus is associated with high morbidity and mortality. To our knowledge, this will be the fourth published case of attempted intestinal salvage with systemic thrombolytic therapy, and the first to report long-segment intestinal stricture as a potential outcome after initial intestinal salvage<sup>[1,2]</sup>.

Tissue plasminogen activator was first approved in the 1980s for successfully reducing clot burden in adults with coronary, cerebral, or pulmonary thrombosis<sup>[6]</sup>. Early reports of its use in the pediatric population targeted catheter-associated arterial thrombosis<sup>[7]</sup>. Since then, pediatric intensive care units have used tPA for life or limb-threatening arterial thrombosis. In addition, Levy first reported improvement after arterial thrombi with systemic tPA infused at 0.1 to 0.5 mg/kg/hour in the neonatal population<sup>[8]</sup>. This thrombolysis was found to rapidly improve vessel patency, limiting ongoing ischemia and improving long-term outcomes<sup>[6]</sup>. In the adult population, mesenteric ischemia secondary to arterial or venous thrombi is commonly managed with surgical or endovascular revascularization; however, catheter-directed thrombolysis as single therapy or in combination with surgical intervention has also been demonstrated to successfully restore perfusion<sup>[9]</sup>. Based on this literature, Kiely published the first two cases of

successful dissolution of mesenteric thrombi after neonatal midgut volvulus by using systemic tPA<sup>[2]</sup>. Applying a similar approach to the Kiely group, Messaoudi also demonstrated significant clinical improvement and intestinal salvage with use of systemic tPA after de-rotation of a midgut volvulus with associated mesenteric ischemia<sup>[1]</sup>.

Given the differing anatomy, physiology, and pharmacologic response of infants compared to adults, reported continuous tPA dosing has been based upon thrombolysis guidelines for limb-affecting arterial occlusion in neonates<sup>[10]</sup>. Kiely published their protocol for thrombolysis with tPA administration at a dose of 0.25 to 0.5 mg/kg per hour for 6 hours with fresh frozen plasma used to increase plasminogen and thereby potentiate the thrombolytic effects<sup>[1,2]</sup>. As new literature emerges supporting thrombolysis in the neonatal population, recent evidence has showed that even lower tPA dosing may be beneficial. Dosing of intravenous tPA at 0.03-0.06 mg/kg per hour for up to 48 hours induced clot lysis in 81% of patients, with only 27% of patients experiencing minor bleeding<sup>[11]</sup>. Therefore, this alternative dosing regimen may be considered in patients who have an increased risk of bleeding.

Despite the successful use of systemic tPA by Kiely and Messaoudi and one successful case using urokinase by Fascetti Leon, no additional reports of mesenteric reperfusion with thrombolysis after a Ladd's procedure for midgut volvulus have been published since 2017<sup>[1, 2,12]</sup>. Furthermore, there is little known about the potential complications and long-term outcomes after tPA administration for intestinal ischemia. One patient was reported to have developed a short-segment jejunal stricture, which was resected six weeks after the index operation, and all of the patients in the aforementioned case reports were discharged from the NICU having achieved enteral autonomy<sup>[1,2]</sup>. Our case is the first report of an apparent remarkable recovery of the majority of the ischemic small intestine after initial tPA administration, but ultimately developed an extensive luminal stricture. Because the intestinal mucosa receives the majority of blood flow to the small bowel, it is most susceptible to damage when blood flow is disrupted. Injury may be confined to the mucosa and submucosa or may extend transmurally. In our patient, despite the improved external appearance of the bowel serosa at the second-look laparotomy, we hypothesize that the ischemic injury to the mucosa was likely irreversible and progressed to the long-segment stricture that ultimately required extensive resection. Despite studies showing successful use of tPA in neonates with arterial thrombi, it is important to note that systemic thrombolysis in neonates with mesenteric ischemia after midgut volvulus does not restore full-thickness intestinal perfusion in all cases<sup>[13]</sup>. In addition, Amano published a case report of catastrophic neonatal midgut volvulus with patchy full-thickness small intestine necrosis, which was thought to be non-viable<sup>[14]</sup>. A second-look laparotomy approach was used without systemic thrombolysis, after which a section of full-thickness necrosis was able to be preserved and regenerate. The neonate resumed normal bowel function after

one month. The second-look laparotomy approach has also been reported in the literature, however, Amano notes that this approach relies on moderate blood flow to the damaged areas to enable intestinal regeneration<sup>[14-17]</sup>.

While the long-segment luminal stricture was a surprising and disappointing finding in our patient, tPA administration was ultimately still a success, likely sparing our patient full-thickness intestinal necrosis and perforation, sepsis, and potentially death. At initial laparotomy only 10 cm of viable proximal intestine was observed, which may not have been compatible with life. After tPA administration and despite the stricture and extensive intestinal resection, our patient ultimately had 47 cm of small intestine remaining. In the months prior to her final laparotomy while on TPN, the small intestine became dilated proximal to the obstruction, which allowed for the performance of a STEP intestinal lengthening procedure as an infant. A review of the STEP registry noted 47% of infants undergoing STEP were able to achieve enteral autonomy<sup>[15]</sup>, which we anticipate may also be the eventual outcome for our patient.

## CONCLUSION

This report presents the utilization of an institutional guideline for thrombolysis in acute mesenteric ischemia secondary to neonatal midgut volvulus. This case highlights the variability in outcomes after intestinal salvage with tPA after midgut volvulus and the importance of thoughtful parental counseling prior to thrombolysis. Thrombolysis with continuous infusion of tPA is a promising treatment, and with the assistance of clinical guidelines, close monitoring of hematologic parameters, and multidisciplinary collaboration, it may improve the care provided to neonates with mesenteric ischemia after midgut volvulus. However, a multi-center prospective study is needed to clearly delineate the risks and benefits of thrombolysis after midgut volvulus.

## DECLARATIONS

Ethics approval and consent to participate: The institutional ethics committee endorsed the study by means of Minutes No. 71 550-23. Due to the design of the study, no informed consent was required.

## CONSENT FOR PUBLICATION:

Not applicable.

## AVAILABILITY OF DATA AND MATERIAL

All data generated or analyzed during this study are included in this published article.

## COMPETING INTERESTS:

The authors declare that they have no competing interests.

**FUNDING:**

This research did not receive any specific grant from funding agencies in the public, commercial, or non-for-profit sectors.

**AUTHORS' CONTRIBUTIONS:**

All authors participated in study conception and protocol elaboration. Data collection was carried out by M.E.R.B. Manuscript drafting was carried out by L.C.G.V. Figure preparation was carried out by A.I.L.L and J.J.V.H. All authors read and approved the final manuscript.

**ACKNOWLEDGEMENTS:**

Not applicable.

**CONFLICT OF INTERESTS**

"The authors declare that they have no competing financial or non-financial interests" in this section.

**REFERENCES**

- Messaoudi, N., *et al.*, Thrombolysis for Severe Intestinal Ischemia due to Midgut Volvulus in a Neonate. *European J Pediatr Surg Rep*, 2015. 3(2): p. 74-7.
- Kiely, E.M., *et al.*, Clot dissolution: a novel treatment of midgut volvulus. *Pediatrics*, 2012. 129(6): p. e1601-4.
- Adams, S.D. and M.P. Stanton, Malrotation and intestinal atresias. *Early Hum Dev*, 2014. 90(12): p. 921-5.
- Sigalet, D.L., Short bowel syndrome in infants and children: an overview. *Semin Pediatr Surg*, 2001. 10(2): p. 49-55.
- Kanellos-Becker, I., *et al.*, Early prediction of complex midgut volvulus in neonates and infants. *Pediatr Surg Int*, 2014. 30(6): p. 579-86.
- Tarango, C. and M.J. Manco-Johnson, Pediatric Thrombolysis: A Practical Approach. *Front Pediatr*, 2017. 5: p. 260.
- Kennedy, L.A., *et al.*, Successful treatment of neonatal aortic thrombosis with tissue plasminogen activator. *J Pediatr*, 1990. 116(5): p. 798-801.
- Levy, M., *et al.*, Tissue plasminogen activator for the treatment of thromboembolism in infants and children. *J Pediatr*, 1991. 118(3): p. 467-72.
- Stone, J.R. and L.R. Wilkins, Acute mesenteric ischemia. *Tech Vasc Interv Radiol*, 2015. 18(1): p. 24-30.
- Ade-Ajayi, N., *et al.*, Acute neonatal arterial occlusion: is thrombolysis safe and effective? *J Pediatr Surg*, 2008. 43(10): p. 1827-32.
- Wang, M., *et al.*, Low-dose tissue plasminogen activator thrombolysis in children. *J Pediatr Hematol Oncol*, 2003. 25(5): p. 379-86.
- Fascetti Leon, F., *et al.*, Urokinase thrombolysis as a rescue treatment for midgut volvulus ischemia. *Journal of Pediatric Surgery Case Reports*, 2017. 23: p. 29-31.
- Leong, R., *et al.*, Use of thrombolytic agents to treat neonatal thrombosis in clinical practice. *Blood Coagul Fibrinolysis*, 2022. 33(4): p. 193-200.
- Amano, H., *et al.*, Full-thickness small intestine necrosis with midgut volvulus, distributed in a patchy fashion, is reversible with moderate blood flow: resumption of normal function to non-viable intestine. *Nagoya J Med Sci*, 2014. 76(3-4): p. 375-80.
- Hoffman, M.A., *et al.*, Management of catastrophic neonatal midgut volvulus with a silo and second-look laparotomy. *J Pediatr Surg*, 1992. 27(10): p. 1336-9.
- McCullagh, M., D.C. Garvie, and E.H. Dykes, A new method of intestinal salvage for severe small bowel ischemia. *J Pediatr Surg*, 1994. 29(9): p. 1231-3.
- Houben, C.H., S. Mitton, and S. Capps, Malrotation volvulus in a neonate: a novel surgical approach. *Pediatr Surg Int*, 2006. 22(4): p. 393-4.