

CASE REPORTS

Open Access



Tubular colonic duplication: a case report and brief review of the literature

Rasem Keilani¹ , Raed Al Taher² , Ghayda' Bader¹ , Leen Hajeer¹ , Taima Bader^{1*} and Balqis Alfreijat¹

Abstract

Background The occurrence of complete tubular colonic duplication is exceedingly rare. In most cases, resection of the duplicated colon may not be possible because of common blood supply with a single mesentery shared between the duplication and associated original bowel (Karkera et al., *Pediatr Gastroenterol Hepatol Nutr* 18:197-201, 2015).

Case presentation In this paper, we present a case of a 9-month-old girl who was noticed to pass stools through her vagina since birth despite normal anus in place, in association with constipation and pain on defecation. On local examination, a vestibular fistula was found. Further management including fistulogram, barium enema, and laparoscopy were performed. She was found to have tubular T-shaped colonic duplication with separate lumens from the mid-transverse colon downwards. Due to a shared fused wall, a decision was made to create a side-to-side (window) anastomosis at descending colon level using GIA staplers and end-to-side anastomosis at a sigmoid level between duplicated and normal colons with (mucosectomy) of duplicated colon down to the perineum.

Conclusions Tubular colonic duplication should be kept in mind in patients presenting with vestibular fistula and fecal soiling in the presence of a normal anus. Minimal-invasive procedures are a safe and good alternative.

Keywords Infant, Intestinal duplication, Tubular colonic duplication, Minimal invasive surgery

Background

Enteric duplications have been described throughout the entire gastrointestinal tract as rare combination anomalies, and they can be either tubular or cystic [1].

Cystic duplications are more common than tubular duplications according to a review of 96 patients with 101 duplications seen over the last 37 years, in which 75 duplications were cystic and 26 were tubular [2]. The most common location for duplication is the ileum, while colonic duplication is rare, accounting for 6–13% of all gastrointestinal duplications, commonly located in the cecum [2].

Tubular colonic duplications are a double muscular layer and epithelium similar to the rest of the colon [3, 4]. Both lumina may be unobstructed and function normally as two perineal ani or terminate distally blindly as imperforate anus of one or both lumina. In some cases, the ventral colon may end as a recto urinary, rectovaginal, or vestibular fistula [4].

The presenting features are constipation, vomiting, volvulus, perforation, and, most commonly, intestinal obstruction due to compression of the normal bowel by the blind end of the duplication [5]. Associated anomalies include genitourinary duplications; skeletal anomaly bladder exstrophy; and malrotation of the gut, omphalocele, and Meckel's diverticulum [3–5]. In the absence of other associated malformations or an ectopic opening, tubular duplications of the colon remain unnoticed, until complications warrant surgical intervention.

Gastrointestinal duplications can present a diagnostic as well as a therapeutic challenge to the surgeons, and as

*Correspondence:

Taima Bader
taimabader@hotmail.co.uk

¹ Amman, Jordan

² Jordan University Hospital, Amman, Jordan

these lesions are unusual to see, they are often not under suspicion until encountered intraoperative [6].

These lesions, if found incidentally, should be managed surgically to prevent any further complications in the future. Future complication as adenocarcinoma arising in a tubular duplication of the jejunum had been reported in 73 years old man [7].

We report a case of tubular colonic duplication starting from the mid-transverse colon in a 9-month-old female infant passing stools from a normal anal opening and a fistulous opening in the vestibule.

Case presentation

History and physical examination

A vaginally delivered, full-term 9-month-old girl with a complaint by her mother of fecal soiling from her vagina since birth; constipation of 2 months duration with pain on defecation, no fever nor vomiting. The examination result was that the abdomen was slightly rigid with no palpable masses; the native anus was within the normal anatomical position, shape, and size. The interrelated perineal examination displayed normal external genitalia with fecal soiling (Fig. 1). Rectovaginal fistula was suspected. Therefore, she underwent EUA to confirm a diagnosis and possible surgical excision of the fistula with the repair of the area. Upon inserting a tube inside the fistulous opening, it did not come out through the anus as expected.

Investigations and diagnostic procedures

A fistulogram was performed using gastrograffin contrast, which showed narrowed segment at the beginning with a nearly normal colon; based on this, the radiologist

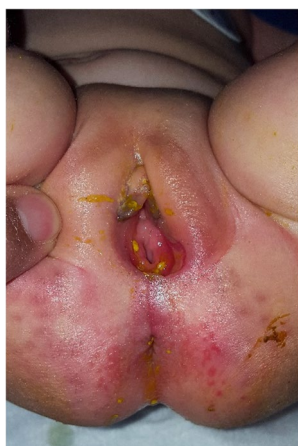

Fig. 1 Perineal examination displayed a native anus that is within the normal anatomical position, shape, and size, with normal external genitalia and fecal soiling

suggested an initial diagnosis of a high perianal fistula with an internal opening at the sigmoid colon (Fig. 2).

Not convinced with the radiology opinion, we decided to do another trial under GA with methylene blue dye injected through a tube inserted inside the fistula and gauze inserted inside the anus. The dye passed through the colon without any passage of methylene blue through the anus as evidenced by a clean gauze, suggesting two separate systems with the absence of communication at that level and a wrong initial diagnosis. A new diagnosis of colonic duplication was discussed.

A double contrast study by barium enema and fistulogram at the same time was performed (Figs. 3 and 4).

Radiologists abstain from giving us a report about the findings of the study may be due to a lack of experience in such rare cases. From our experience with similar cases after studying the films, the diagnosis of colonic duplication was more likely.

To be sure of the diagnosis, a diagnostic confirmatory laparoscopy was performed. Laparoscopic exploration of the colon confirmed the diagnosis of colonic duplication. It revealed tubular T-shaped colonic duplication with separate lumens from the mid-transverse colon downwards; both colons were found entirely attached at the mesenteric side sharing both vascularity and wall (Fig. 5). The duplicated colonic segment towards the mesenteric side terminated downward at the vestibule.

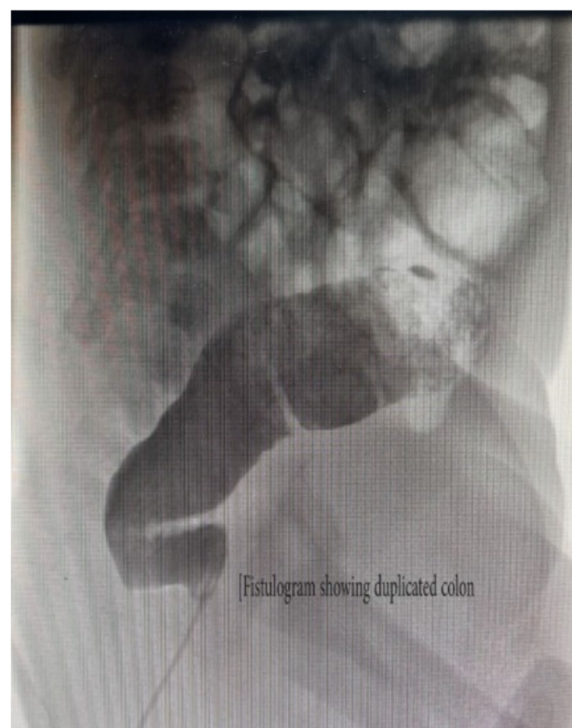

Fig. 2 A fistulogram showing narrowed segment distally with a nearly normal colon proximally

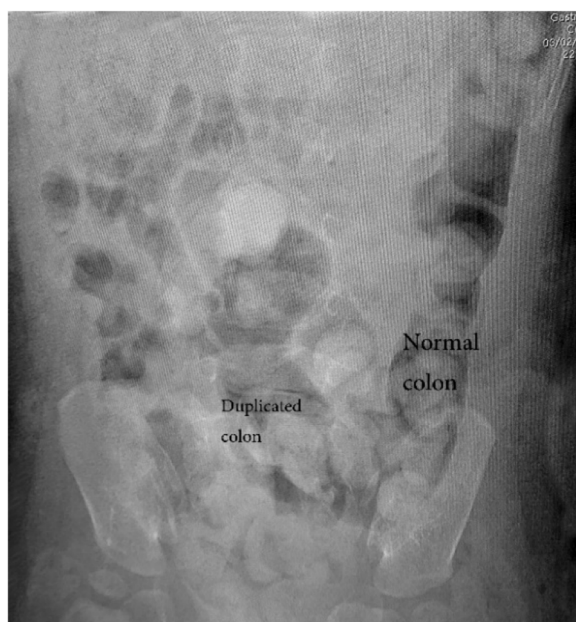

Fig. 3 Plain abdominal X-ray before a double contrast study

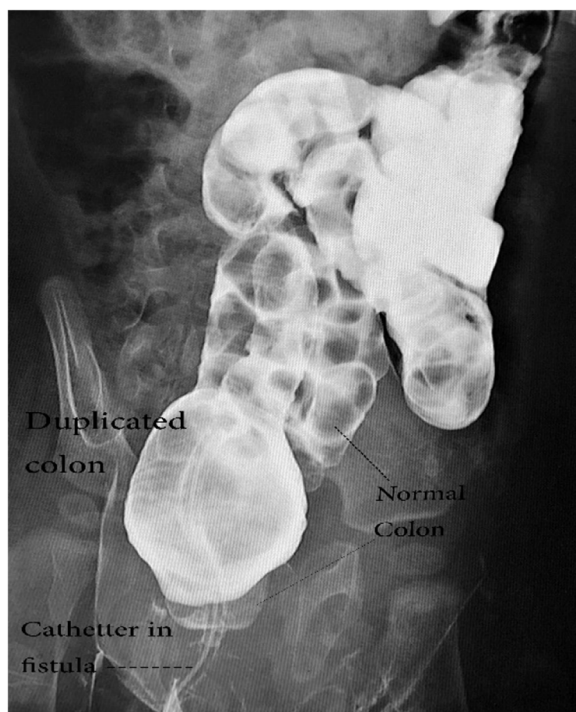


Fig. 4 Simultaneous contrast enema and fistulogram study

Operative treatment

Laparotomy was then done using a lazy transverse incision in the lower abdomen. The duplicated colon was fused to the native colon in a double-barrel fashion (Fig. 6).

A side-to-side (window) anastomosis between the native colon and the duplicated colon was performed using a GIA stapler at the descending segment, converting 6 cm into a single-wide lumen (Fig. 7).

Duplicated colon was cut at the sigmoid level; the proximal end was used to create an end-to-side anastomosis with a normal colon—these two minimally invasive procedures ensure complete drainage of the content of duplicated colon into the normal colon (Fig. 8).

The distal segment of the duplicated colon was opened down to peritoneal reflection; stripping of the mucosa of the distal duplicated colon down to the fistula opening was done (Fig. 9).

The stripped mucosa was transfixed to the feeding tube inserted through the fistula and inverted totally out of the fistula opening; it was cut, and the area was repaired to close the site of the fistula (Fig. 10).

Outcome

The biopsy pathology report revealed unremarkable colorectal mucosa and submucosa with mild chronic inflammation, with no evidence of malignancy.

The patient was discharged on day 10 in good general condition after an uneventful postoperative clinical course. She was passing stool normally through the anal opening. At follow-up evaluation, the patient was doing well without pain or constipation.

Discussion

Gastrointestinal (GI) duplications are congenital anomalies of partial or complete parallel growth of a twin segment of the intestine; the majority of them are cystic (80%) and occur on the mesenteric side of the bowel. Tubular colonic duplications account for over 13% of all duplications mostly in the cecum. GI duplication is seen at approximately 1:4500 with an equal male-to-female ratio. When the following criteria are met, duplications of the alimentary tract are confirmed (1) adherent to some part of the alimentary tract, (2) contain a double smooth muscular coat, and (3) internal surface is lined by enteric mucosa [8].

The most common clinical presentations of colonic duplications are intestinal obstruction, constipation, vomiting, and hematochezia. Since the abdominal symptoms are vague, most patients remain undiagnosed unless complications like volvulus, perforation, and malignancy developed [9].

Long tubular duplications have a higher frequency of associated anomalies, including duplications of the GU system, skeletal anomaly bladder exstrophy, malrotation of the gut, omphalocele, and Meckel's diverticulum,

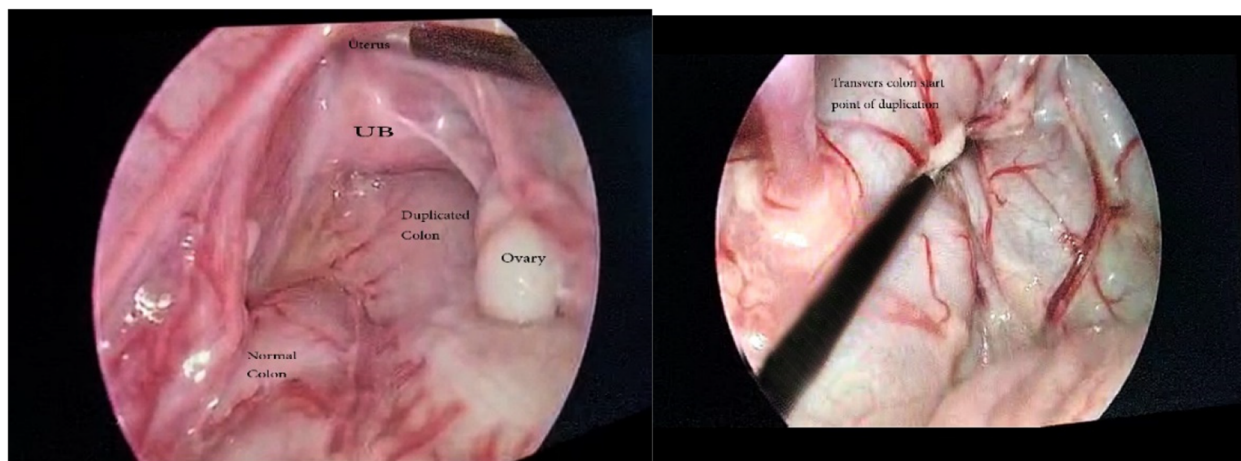


Fig. 5 Laparoscopic exploration of the colon confirming the diagnosis of colonic duplication, from the mid-transverse colon terminating downward at the vestibule

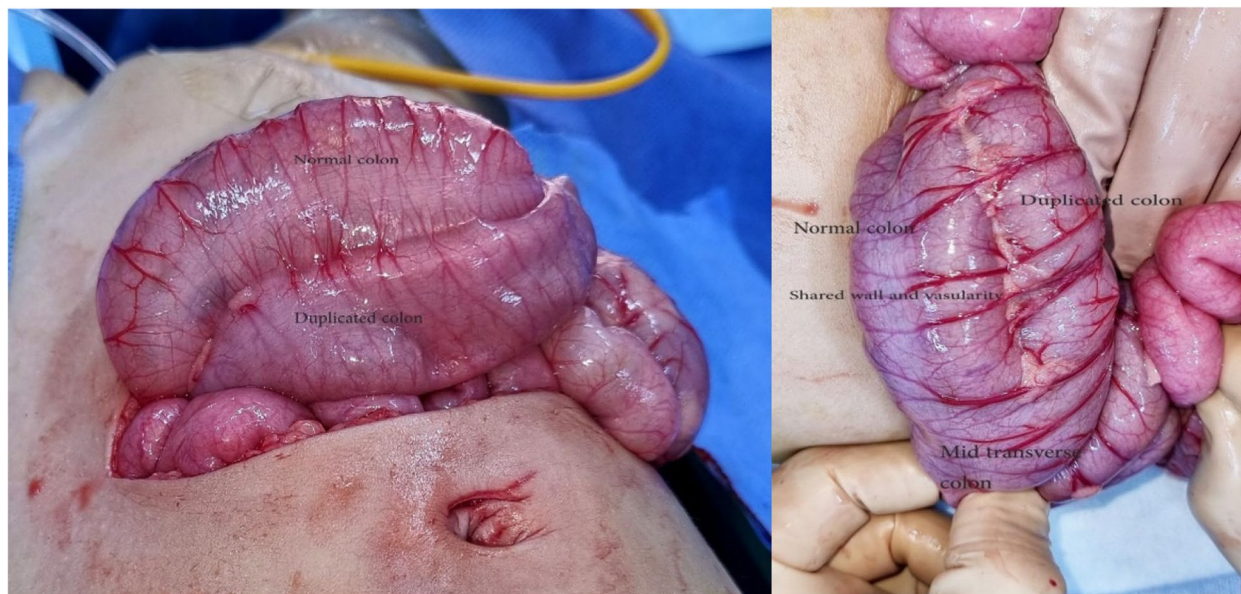


Fig. 6 Laparotomy exploration showing the duplication at the sigmoid area (on the left) and at the mid-transverse colon (on the right)

supporting the partial twinning theory of embryogenesis [3–5, 10, 11].

CT or MRI scans are commonly used to make a diagnosis. However, the anatomy of any communication with the native GI or GU systems can be delineated using contrast enema.

The type, size, and related anomalies all influence how colonic duplications are treated. Small cystic duplications are usually treated with enucleation or resection and anastomosis in the same way that small bowel duplications are. Long tubular duplications are difficult to treat, and each patient’s treatment must be adapted to his or

her specific circumstances. Many surgeons believe that resection with colectomy is excessively aggressive, but it is recommended in most instances to prevent complications such as malignancy transformation. Stool softeners are frequently used to help in long tubular duplications with distal connections. If there is no distal communication, it may be necessary to construct one to alleviate occlusion. Excision and closure of fistulous tracts to the perineum or other organs is required. Associated anomalies also need attention [12].

In our case, the infant has a vestibular fistula with soiling of stools due to tubular colonic duplication from

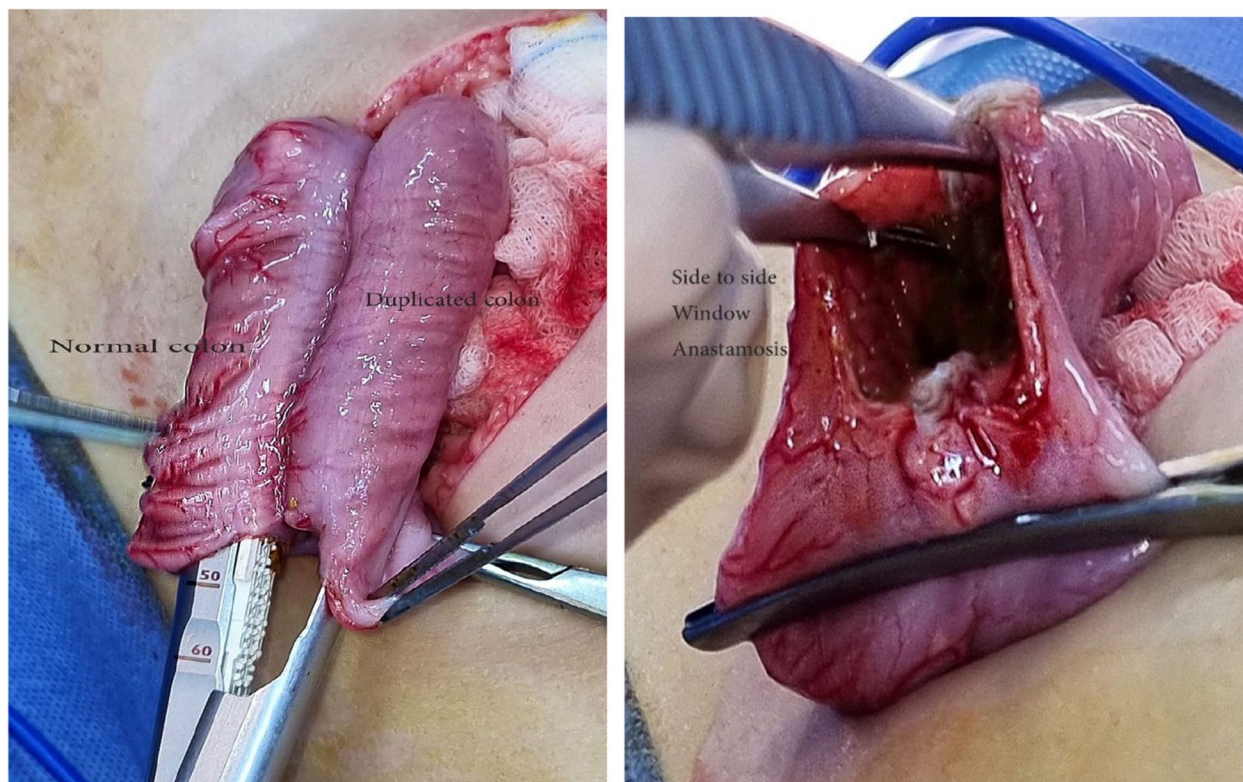


Fig. 7 A side-to-side (window) anastomosis between the native colon and the duplicated colon was performed using a GIA stapler

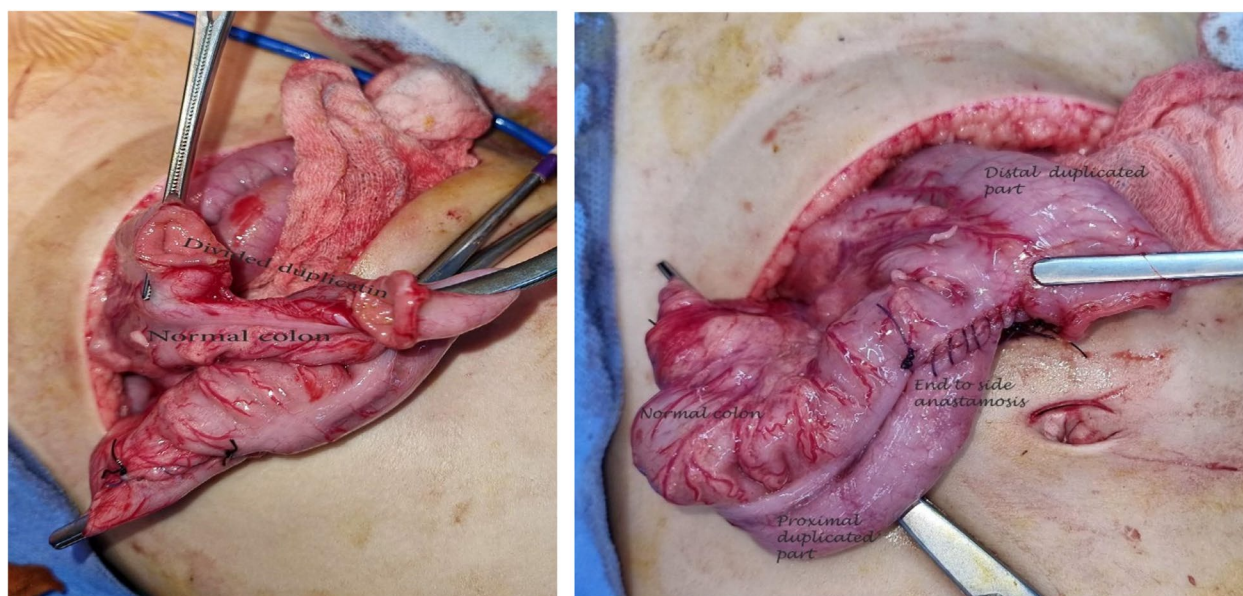


Fig. 8 Duplicated colon was cut at the sigmoid level; the proximal end was used to create an end-to-side anastomosis with the normal colon

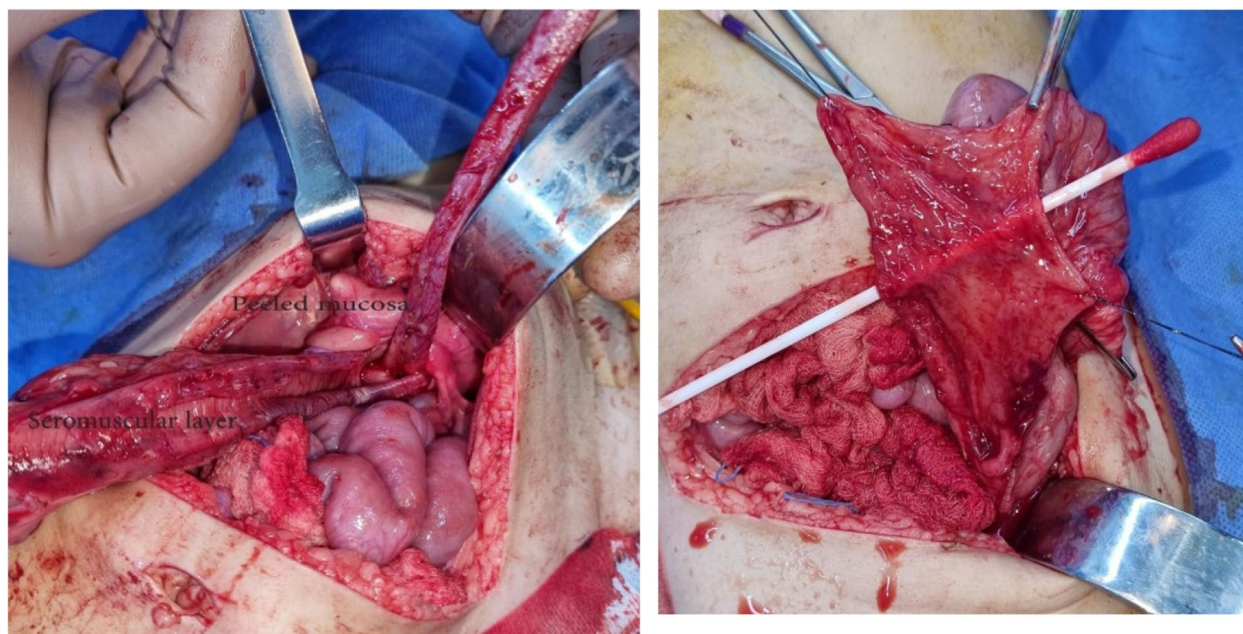


Fig. 9 The distal segment of the duplicated colon was opened down to peritoneal reflection (on the left); stripping of the mucosa of the distal duplicated colon down to the fistula opening (on the right)

mid-transverse colon down to the fistula. Because of the shared vascular supply, the common wall and age of the patient’s duplicated colon could not be removed without the excision of practically half of the colon. The patient tolerated the procedures with no surgical complications, and she passed stool normally via the anal canal in a few days postoperatively.

Conclusions

In conclusion, tubular colonic duplication should be kept in mind in patients with vestibular fistula and fecal soiling in the presence of a normal anus, chronic abdominal distension, and severe constipation. In addition, TCD is associated with many anomalies that should be looked for while evaluating the patient.

Surgical treatment methods differ due to the different characteristics and localizations of the duplication, but usually, there is no total resection of the colon due to shared vasculature with the normal colonic lumen. Minimal-invasive procedures are a safe and good alternative.

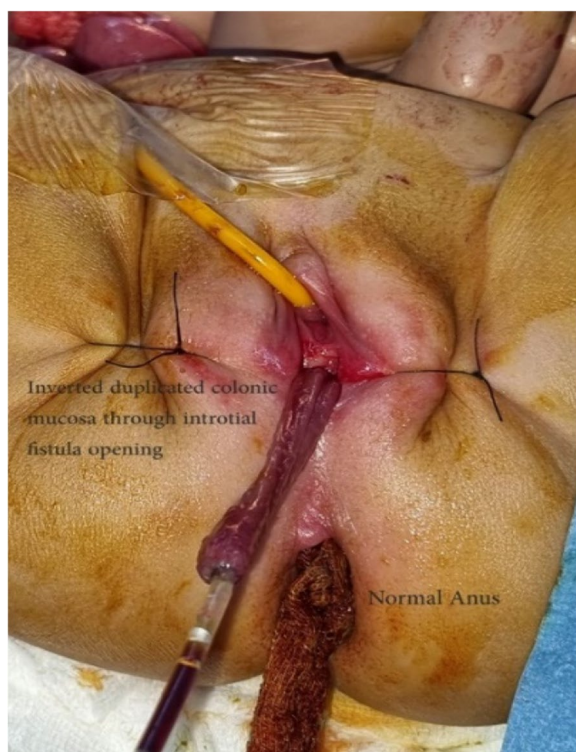


Fig. 10 The stripped mucosa was transfixed to the feeding tube inserted through the fistula and inverted totally out of the fistula opening; then, it was cut and closed

Abbreviations

- GIA stapler Gastrointestinal anastomosis stapler
- EUA Examination under anesthesia
- GI Gastrointestinal
- GU Genitourinary
- CT Computed tomography
- MRI Magnetic resonance imaging
- TCD Tubular colonic duplication

Acknowledgements

All people that participated in this paper are listed as co-authors. No acknowledgement.

Authors' contributions

RK is the principal investigator that generated the study idea, performed the surgery, followed up with the patient, and revised and edited the manuscript. RT is the physician that followed up with the patients clinically and provided data for the study. Balqis and Leen have written the introduction. Taima and Leen have written the case presentation and abstract section, collected the images, and double-checked the collection of case data. Ghayda' has written the discussion and conclusions section. The authors read and approved the final manuscript.

Funding

None received.

Availability of data and materials

All data generated or analyzed during this study are included in this published article.

Declarations**Ethics approval and consent to participate**

The study has been approved by the local Institutional Review Board, under the reference number: 4102022.

Consent for publication

Written informed consent was obtained from the patient's parents for the publication of this case report and accompanying images.

Competing interests

The authors declare that they have no competing interests.

Received: 30 July 2022 Accepted: 28 July 2023

Published online: 30 August 2023

References

1. Stern LE, Warner BW. Gastrointestinal duplications. *Semin Pediatr Surg.* 2000;9(3):135–40. <https://doi.org/10.1053/spsu.2000.7565>. PMID: 10949423.
2. Karkera PJ, Bendre P, D'souza F, Ramchandra M, Nage A, Palse N. Tubular colonic duplication presenting as rectovestibular fistula. *Pediatr Gastroenterol Hepatol Nutr.* 2015;18(3):197–201. <https://doi.org/10.5223/pghn.2015.18.3.197>. Epub 2015 Sep 25. PMID: 26473141; PMCID: PMC4600705.
3. Macpherson RI. Gastrointestinal tract duplications: clinical, pathologic, etiologic, and radiologic considerations. *Radiographics.* 1993;13:1063–80.
4. Kaur N, Nagpal K, Sodhi P, Minocha VR. Hindgut duplication—case report and literature review. *Pediatr Surg Int.* 2004;20:640–2.
5. Jellali MA, Mekki M, Saad J, Zrig A, Elanes I, Mnari W, et al. Perinatally discovered complete tubular colonic duplication associated with anal atresia. *J Pediatr Surg.* 2012;47:e19–23.
6. Ildstad ST, Tollerud DJ, Weiss RG, Ryan DP, McGowan MA, Martin LW. Duplications of the alimentary tract clinical characteristics, preferred treatment, and associated malformations. *Ann Surg.* 1988;208(2):184–9.
7. Kusunoki N, Shimada Y, Fukumoto S, Iwatani Y, Ohshima T, Arahi E, Miyazaki N, Maeda S. Adenocarcinoma arising in a tubular duplication of the jejunum. *J Gastroenterol.* 2003;38(8):781–5. <https://doi.org/10.1007/s00535-002-1146-8>. PMID: 14505134.
8. Kottra JJ, Dodds WJ. Duplication of the large bowel. *Am J Roentgenol Radium Ther Nucl Med.* 1971;113:310–5.
9. Fuchs JR, Clark K, Breckler FD, et al. Complete colonic duplication—a case report. *J Pediatr Surg.* 2008;43:E11–3.
10. Smith ED, Stephens FD. Duplication and vesicointestinal fissure. *Birth Defects Orig Artic Ser.* 1988;24:551–80.
11. Ravitch MM. Hindgut duplication—doubling of colon and genital urinary tracts. *Ann Surg.* 1953;137:588–601.

12. Russell KW, Holcomb GW III. Alimentary tract duplications. *Holcomb and Ashcraft's Pediatric Surgery Book.* 9780323549776.

Publisher's Note

Springer Nature remains neutral with regard to jurisdictional claims in published maps and institutional affiliations.

Submit your manuscript to a SpringerOpen® journal and benefit from:

- Convenient online submission
- Rigorous peer review
- Open access: articles freely available online
- High visibility within the field
- Retaining the copyright to your article

Submit your next manuscript at ► [springeropen.com](https://www.springeropen.com)