

ORIGINAL RESEARCH

Open Access



Clinical and manometric evaluation of postoperative anorectal function in patients after trans-anal pull-through for Hirschsprung disease

Hamidreza Foroutan¹, Farhad Homapour^{2*}, Mohsen Dehghani³, Hamid Reza Niazkar⁴, Hoda Sufi⁵ and Behdad Zibae⁶

Abstract

Background Transanal endorectal pull-through (TEPT) surgery is a new trend in the treatment of Hirschsprung disease, and evaluating its functional outcome is difficult. The purpose of this study is to evaluate the defecation pattern after TEPT surgery in pediatrics.

Material and methods In this cross-sectional survey, 40 patients with Hirschsprung disease were studied. They underwent a one-stage transanal pull-through procedure from May 2007 till April 2015 in Namazi hospital by the same surgeon. All the patients had the aganglionic segment in the rectosigmoid, confirmed by pre-operation barium enema and post-operation histopathology. The patients were 40 children with mean operation age of 36.6 months old. The success rate of surgery was evaluated by following the questionnaire form. Clinical evaluation with bowel function score and anorectomanometry were carried out.

Result One hundred percent of them had a daily stool. Eighty-five percent of patients never experienced pain during defecation, 10% experienced occasional pain, and the rest felt pain with every defecation. Just one case (5%) reported using a laxative. Regarding improvements after the operation, 75% were completely okay, 20% felt much better, and 5% reported some improvements. The average National Health Service score was 8.375, which seems satisfactory. The mean average anal sphincter in the group with soiling was 39.67 and in the group without soiling was 34.83, which is in the normal range in both groups, and there was no significant difference between these groups ($P > 0.05$).

Conclusion The defecation pattern after TEPT surgery were satisfactory in almost all cases, even in infancy. Most patients had satisfactory manometry and clinical result.

Keywords Hirschsprung disease, Transanal endorectal pull-through, Manometry, RAIR

*Correspondence:

Farhad Homapour
fhomapoor@gmail.com

¹ Department of Pediatric Surgery, Namazi Hospital, Shiraz University Laparoscopy Research Center, Shiraz University of Medical Sciences, Shiraz, Iran

² Oncosurgery Fellowship, Department of Surgery, School of Medicine, Shiraz University of Medical Sciences, PO Box: 9691793718, Shiraz, Iran

³ Departments of Pediatric Gastroenterology, Gastroenterohepatology Research Center, Shiraz University of Medical Sciences, Shiraz, Iran

⁴ Breast Diseases Research Center, Shiraz University of Medical Sciences, Shiraz, Iran

⁵ Department of Pediatrics, School of Medicine, Zahedan University of Medical Sciences, Zahedan, Iran

⁶ Student Research Committee, Gonabad University of Medical Sciences, Gonabad, Iran



© The Author(s) 2023. **Open Access** This article is licensed under a Creative Commons Attribution 4.0 International License, which permits use, sharing, adaptation, distribution and reproduction in any medium or format, as long as you give appropriate credit to the original author(s) and the source, provide a link to the Creative Commons licence, and indicate if changes were made. The images or other third party material in this article are included in the article's Creative Commons licence, unless indicated otherwise in a credit line to the material. If material is not included in the article's Creative Commons licence and your intended use is not permitted by statutory regulation or exceeds the permitted use, you will need to obtain permission directly from the copyright holder. To view a copy of this licence, visit <http://creativecommons.org/licenses/by/4.0/>.

Background

Hirschsprung disease is a congenital intestinal disorder characterized by the absence of intrinsic ganglion cells in the myenteric and submucosal plexuses of the distal intestine [1]. Since these cells are in charge of normal peristalsis, patients with Hirschsprung disease manifest intestinal obstruction at the level of aganglionosis during the newborn period or with constipation in infancy [2]. Hirschsprung disease is approximately 1 in 5000 live-born infants. In most cases, patients present with obstructive intestinal symptoms such as failure to pass meconium within the first 48 h, abdominal distension, or bilious vomiting [3]. Aganglionosis mainly involves the rectum or rectosigmoid, even though the entire colon or small intestine may be involved in some cases. The diagnosis of Hirschsprung disease relies on histological examination of the rectal biopsy specimen. Also, there are other methods for diagnosing Hirschsprung disease, such as anorectal manometry and water-soluble contrast enema [4–6].

The recto-anal inhibitory reflex (RAIR) is a noninvasive test to assess anorectal physiology without the requirement of anesthesia. It is a reflex relaxation of the internal anal sphincter in response to rectal distension. RAIR is absent in children with Hirschsprung disease because the aganglionic segment impairs the relaxation of the internal sphincter due to rectal distention [7].

In most cases, treatment of Hirschsprung disease is surgical. The operative principle for Hirschsprung disease is to remove the aganglionic segment and reconstruct the intestinal tract by attaching the normally innervated bowel to the anus while preserving normal sphincter function [8–10]. Many types of pull-through procedures have been established worldwide, and the most commonly performed ones are the Swenson, Duhamel, and Soave (endorectal pull-through) procedures [11]. De La Torre-Mondragon introduced the transanal modified Soave approach and Transanal endorectal pull-through (TEPT) in 1998 [12]. TEPT procedure protects the patient from colostomy complications and has several advantages compared to classical pull-through techniques, such as shorter hospital stays, postoperative ileus, bleeding, and pain. At the same time, no intraperitoneal adherence or scarring is reported. TEPT has proved to be as beneficial as the older multi-stage procedures since patients benefit from fewer operations and reduced healthcare costs due to shorter hospital stays [13].

After resectioning, the aganglionic colorectum, surgery for Hirschsprung disease, endorectal or retrorectal pull-through, and coloanal anastomosis surgery consists of colon mobilization [14, 15]. Pelvic nerve injury is one of the rare complications of TEPT surgery. However, this procedure can cause incontinence by sphincter injuries,

nerve supply damage due to anal sphincter stretching, and nerve ending damage due to distal anorectal anastomosis near the dentate line. Common postoperative complications of Hirschsprung disease include bowel obstruction, enterocolitis, and fecal incontinence. Hence, anorectal manometry have been used to work up patients for these complications [12].

Anorectal manometry has been used to study the physiology of the anorectum. It can evaluate the resting anal pressure, rectoanal inhibitory reflex, and anorectal sensation [16]. However, its application for post-TEPT operation assessment has not been established yet. For this purpose, we conducted a study to validate the use of anorectal manometry as a standard tool for assessment after TEPT operation. With clinical assessment, factors affecting the prognosis of this group of patients were analyzed. Therefore, this study aimed to evaluate the defecation pattern after TEPT surgery in pediatrics.

Materials and methods

In a cross-sectional study, 182 patients with Hirschsprung disease diagnosis were included in the present study. They underwent a one-stage transanal pull-through procedure from May 2007 till April 2015 in Namazi hospital by the same surgeon. The exclusion criteria were (1) patients with severe learning difficulties ($n = 2$), (2) patients with an inability to cooperate during the study ($n = 4$), (3) patients with concomitant anorectal/neurological anomaly ($n = 2$), (4) patients who required reoperation or had laparotomy due to failure of the previous procedure ($n = 2$), and (5) patients with the previous colostomy before operation ($n = 2$). From this population, 130 patients were unwilling to participate in the study and we could enroll just 40 patients who had all of the mentioned criteria. After the operation and during outpatient department follow-up, we asked their parents to sign the enrollment consent and fill out our questionnaire forms. The present study was approved by the ethic and research committees of the participating hospital. The success rate of surgery was evaluated by following the questionnaire form. Clinical evaluation with bowel function score and anorectomanometry were carried out. Sphincter resting pressure between 30 mmHg and 60 mmHg was considered normal.

Patients received standard postoperative care, including wound management, and were eventually required to start enteral feeding according to the individual's bowel recovery. Anal dilatation was started in the early postoperative period. Patients' caregivers were taught the technique of anal dilatation and how to perform the procedure when patients were discharged from the hospital. They were followed up regularly at the outpatient clinic. For those who consented to participate in this

study, a standard questionnaire, the modified form of the questionnaire used in Keshtgar et al.'s study, which was validated in 2000 patients [9, 17], regarding their bowel functions, including frequency of bowel motion, the presence of constipation or soiling and pain during defecation, general health improvement was completed during the interview and named NHS (National Health Service) score (A1), which is provided in the Additional file 1. In our study, patients underwent the test in Namazi hospital, where the primary operation was carried out.

During the manometry assessment, a well-lubricated, water-perfused silicone manometric catheter with side openings and a distensible balloon at its tip was inserted into the rectum. A change in pressure was detected by a transducer, which converted the results into the connecting computer. Various parameters of age-appropriated anorectal physiology, such as sphincteric resting pressure and the presence of rectoanal inhibitory reflex (RAIR), were recorded. No sedation was given to any patient, and the procedure lasted approximately 5–10 min. All patients were discharged after the procedure without any complications.

There is a lack of standard reference for average RAIR value in children. In the current study, normal sphincteric resting pressure is considered between 30 mmHg and 60 mmHg, based on two previous studies regarding anorectal manometry in a pediatric population [9, 10]. A value lower or higher than this range would be considered sphincter hypotonicity or hypertonicity. For positive RAIR, it was defined as a drop-in sphincter pressure for at least 15 mmHg for 5 s when the balloon at the catheter tip was inflated. After collecting data from questionnaire forms and anorectal manometry, patients were divided into two groups regarding if they had any defecation complaints such as soilage, constipation, or incontinence. Then, average anal sphincter resting pressure and RAIR were compared between these two groups. It should be noted that in patients with soiling the pseudo- incontinence was excluded through clinical evaluation of anal sphincter.

Data were collected and analyzed using the software Graphpad Prism Version 6 in a two-tailed *t* test regarding their average resting pressure and RAIR. *P* values were

calculated, and it is considered significant if it is lower than 0.05.

Results

The patients were 40 children with a mean operation age of 36.6 months (max: 11 years old and min: 25 days old, neonates: two patients) (Table 1). Thirty of them (75%) were male, and 10 of them (25%) were female, with a mean range of 4-year follow-ups (Table 1). With a mean range of 4-year follow-up after the operation, 50% of patients never experienced fecal soiling, 15% of them experienced occasional fecal soiling, 15% had soiling only if bowel loaded, 10% had occasional soiling, and the rest had continuous fecal soiling day and night (Fig. 1).

One hundred percent of them had daily stool (Table 1). Eighty-five percent never experienced pain during defecation, 10% experienced occasional pain, and the rest felt pain with every defecation. Just two cases (5%) reported using a laxative. Regarding general health conditions after the operation, 85% were well, 15% were occasionally ill, and 5% were often ill.

About the behavior related to bowel problems, 80% were cooperative, and 20% required reminding to use the lavatory or pot. Regarding improvements after the operation, 75% were completely okay, 20% felt much better, and 5% reported some improvements. In follow-up DRE (digital rectal exam), no fecal impaction was noted in any patients. Also, it should be noted that all the studied

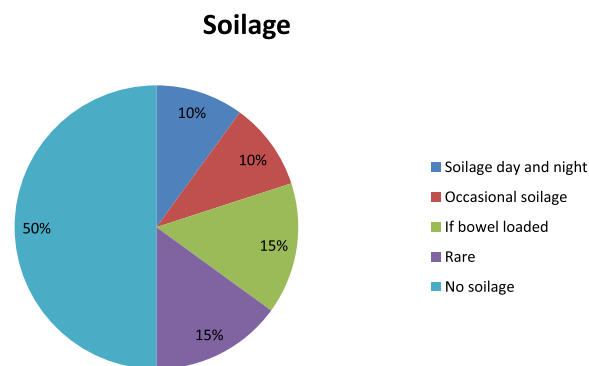


Fig. 1 Soilage rate after TEPT procedure

Table 1 The descriptive analysis of the studied patients

Variables	Population: n = 40		
Age at operation	Mean: 36.6 months/old	Min 25 days/old	Max 11 years/old
Sex	Male; N = 30	Female; n = 10	
Daily stool	100%; N = 40		
Pain during defecation	None; N = 34	Occasionally N = 4	Every time; n = 2

patients had adequate length of anal mucosa above dentate line after the TEPT operation.

The average NHS was 8.375, which seems to be a satisfactory score. The mean average anal sphincter in the group with soiling was 39.67 and in the group without soiling was 34.83, which is in the normal range in both groups, and there was no significant difference between these groups ($P > 0.05$) (Fig. 2). Since all the patients had histopathologic confirmation of aganglionosis, RAIR was absent in the studied patients (Table 1).

Discussion

Swenson and Duhamel are two traditional procedures for treating Hirschsprung disease, and their outcome did not fulfill surgeons’ expectations [18]. Nowadays, TEPT has become the preferable procedure for treating Hirschsprung disease [19]. Like any other surgical procedure, TEPT has some pros and cons.

According to past studies, the TEPT procedure has some advantages, including minimal invasion and a shorter duration of surgery. Dissections are being performed transanally. Thus, in most cases, no abdominal incision is needed. Primary laparotomy is evitable in many cases [20–22]. Consequently, it does not leave any abdominal scar. Also, postoperative ileus, abdominal contamination, and intestinal adhesions are much lesser than in other procedures [23]. TEPT procedure can be performed in the early infantile period, and patients recover shortly after the surgery [24]. Unlike the Duhamel procedure, a lesser residual aganglionic segment in the TEPT procedure leads to a lesser functional obstruction resulting in better postoperative bowel function. However, the TEPT procedure also comes with some disadvantages, including the possibility of injury to the anal sphincter and its nerve supply and pelvic or genitourinary nerve injury, which leads to incontinence and

sexual dysfunction [25]. A very distal anorectal anastomosis near the dentate line may also cause nerve-ending damage leading to incontinence [26–29].

Although the TEPT procedure has shown clear advantages over other procedures, there is a lack of evidence, particularly concerning the long-term continence outcomes [19]. This study aimed to evaluate the defecation pattern after the TEPT surgery. For this purpose, we conducted a study with a mean range of 4-year follow-up after operation. In the present study, the results were gathered from one pediatric surgical center in Shiraz. In the current study, there were more male than female patients, which was expected due to the modality of Hirschsprung disease (75% male) [30–32]. In the current study, the frequency of fecal soiling, a common complication after the TEPT procedure, was 50%. Fortunately, only 4 out of 40 patients experienced soiling continuously, nearly the same as international statics reported in the study by Cheng Zhang [33]. In a study by Till et al. [34], the manometric assessment after TEPT operation was reported to be favorable. They suggested that the functional integrity of the anorectal sphincter complex could be preserved. In another study by Soo-Hong et al. [35], they evaluated the mid- and long-term outcomes of Transanal single-stage endorectal pull-through (TERPT). They demonstrated that the functional outcomes of TERPT performed during the infantile period, were similar to that of the normal population [35].

Conclusion

The current study indicates that the defecation pattern after TEPT surgery were satisfactory in almost all cases, even in infancy. Also, most patients had satisfactory manometry and clinical result after the TEPT surgery. In addition, further studies with longer follow-ups and larger study population are suggested.

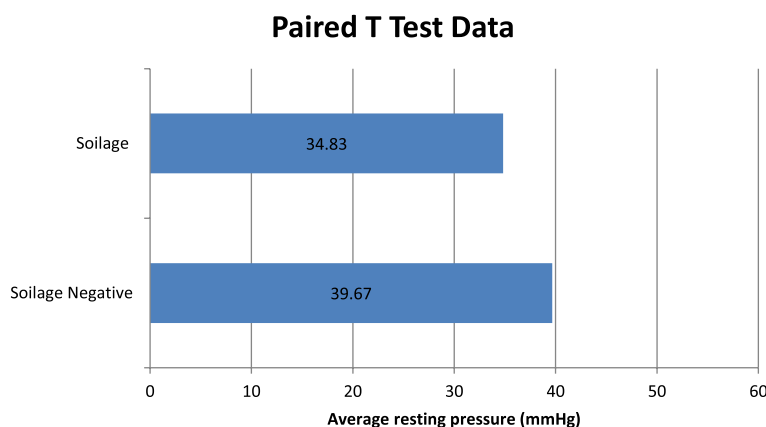


Fig. 2 Average resting pressure in patients with soilage and without soilage

Abbreviations

DRE	Digital rectal exam
NHS	National Health Service
RAIR	Rectoanal inhibitory reflex
TEPT	Transanal endorectal pull-through

Supplementary Information

The online version contains supplementary material available at <https://doi.org/10.1186/s43159-023-00238-y>.

Additional file 1. A1: Adopted NHS questionnaire.

Acknowledgements

The authors would like to acknowledge Shiraz University of Medical Sciences for provide the funding.

Authors' contributions

HF, FH, and MD designed the study, performed the experience and revised the draft. HRN, HS, and BZ analyzed the data and wrote the draft. The author(s) read and approved the final manuscript.

Funding

This study was funded by the Shiraz University of Medical Sciences.

Availability of data and materials

Data will be available upon request to the corresponding author.

Declarations

Ethics approval and consent to participate

The present study was approved by the ethics and research committees of the participating hospital.

Consent for publication

Not applicable.

Competing interests

The authors declare that they have no competing interests.

Received: 6 March 2022 Accepted: 17 December 2022

Published online: 10 January 2023

References

- Puri P, Friedmacher F. Hirschsprung's disease. In: Rickham's neonatal surgery: Springer; 2018. p. 809–28.
- Mattioli G, Faticato MG, Prato AP, Jasonni V. Hirschsprung's disease in newborns. In: Neonatology: Springer; 2017. p. 1–9.
- Bradnock T, Knight M, Kenny S, Nair M, Walker G. Hirschsprung's disease in the UK and Ireland: incidence and anomalies. *Arch Dis Child*. 2017;102(8):archdischild-2016-311872.
- Yoshimaru K, Kinoshita Y, Yanagi Y, Obata S, Jimbo T, Iwanaka T, et al. The evaluation of rectal mucosal punch biopsy in the diagnosis of Hirschsprung's disease: a 30-year experience of 954 patients. *Pediatr Surg Int*. 2017;33(2):173–9.
- Tran VQ, Mahler T, Bontems P, Truong DQ, Robert A, Goyens P, et al. Interest of anorectal manometry during long-term follow-up of patients operated on for Hirschsprung's disease. *J Neurogastroenterol Motil*. 2018;24(1):70.
- Hadidi A. Transanal endorectal pull-through for Hirschsprung's disease: a comparison with the open technique. *Eur J Pediatr Surg*. 2003;13(03):176–80.
- Wu J-F, Lu C-H, Yang C-H, Tsai I-J. Diagnostic role of anal sphincter relaxation integral in high-resolution anorectal manometry for hirschsprung disease in infants. *J Pediatr*. 2018;194:136–41.e2.
- Pakarinen M. Perioperative complications of transanal pull-through surgery for Hirschsprung's disease. *Eur J Pediatr Surg*. 2018;28(2):152–5.
- Keshdgar A, Ward H, Clayden G, de Sousa N. Investigations for incontinence and constipation after surgery for Hirschsprung's disease in children. *Pediatr Surg Int*. 2003;19(1-2):4–8.
- Zhang SC, Bai YZ, Wang W, Wang WL. Stooling patterns and colonic motility after transanal one-stage pull-through operation for Hirschsprung's disease in children. *J Pediatr Surg*. 2005;40(11):1766–72.
- Neuvonen MI, Kyrklund K, Rintala RJ, Pakarinen MP. Bowel function and quality of life after transanal endorectal pull-through for Hirschsprung disease. *Ann Surg*. 2017;265(3):622–9.
- Bing X, Sun C, Wang Z, Su Y, Sun H, Wang L, et al. Transanal pullthrough Soave and Swenson techniques for pediatric patients with Hirschsprung disease. *Medicine*. 2017;96(10):e6209.
- Adigüzel Ü, Ağengin K, Kırıştıoğlu İ, Doğruyol H. Transanal endorectal pull-through for Hirschsprung's disease: experience with 50 patients. *Ir J Med Sci* (1971-). 2017;186(2):433–7.
- Vercillo K, Blumetti J. Pull-through procedures. In: *Complications of anorectal surgery*: Springer; 2017. p. 277–95.
- Pratap A, Gupta DK, Shakya VC, Adhikary S, Tiwari A, Shrestha P, et al. Analysis of problems, complications, avoidance and management with transanal pull-through for Hirschsprung disease. *J Pediatr Surg*. 2007;42(11):1869–76.
- Sultan AH, Monga A, Lee J, Emmanuel A, Norton C, Santoro G, et al. An International Urogynecological Association (IUGA)/International Continence Society (ICS) joint report on the terminology for female anorectal dysfunction. *Neurourol Urodyn*. 2017;36(1):10–34.
- Clayden G, Keshdgar A, Carcani-Rathwell I, et al. The management of chronic constipation and related faecal incontinence in childhood. *Arch Dis Child Educ Pract*. 2005;90(3):ep58-ep673.
- Li T, Li L, Zhuang B, Li H. Long term outcomes for neonates of Hirschsprung's disease undergoing transanal Swenson or Duhamel pull-through by a 5 year follow-up study. *Int J Clin Exp Med*. 2018;11(3):2630–5.
- Romero P, Kroiss M, Chmelnik M, Königs I, Wessel LM, Holland-Cunz S. Outcome of transanal endorectal vs. transabdominal pull-through in patients with Hirschsprung's disease. *Langenbeck's Arch Surg*. 2011;396(7):1027–33.
- Ammar SA, Ibrahim IA. One-stage transanal endorectal pull-through for treatment of Hirschsprung's disease in adolescents and adults. *J Gastrointest Surg*. 2011;15(12):2246–50.
- Minford J, Ram A, Turnock R, Lamont G, Kenny S, Rintala R, et al. Comparison of functional outcomes of Duhamel and transanal endorectal coloanal anastomosis for Hirschsprung's disease. *J Pediatr Surg*. 2004;39(2):161–5.
- So HB, Becker JM, Schwartz DL, Kutin ND. Eighteen year's experience with neonatal Hirschsprung's disease treated by endorectal pull-through without colostomy. *J Pediatr Surg*. 1998;33(5):673–5.
- Hackam DJ, Filler R, Pearl RH. Enterocolitis after the surgical treatment of Hirschsprung's disease: risk factors and financial impact. *J Pediatr Surg*. 1998;33(6):830–3.
- Proctor M, Traubici J, Langer J, Gibbs D, Ein S, Daneman A, et al. Correlation between radiographic transition zone and level of aganglionosis in Hirschsprung's disease: Implications for surgical approach. *J Pediatr Surg*. 2003;38(5):775–8.
- Boemers TM, Bax NM, van Gool JD. The effect of rectosigmoidectomy and Duhamel-type pull-through procedure on lower urinary tract function in children with Hirschsprung's disease. *J Pediatr Surg*. 2001;36(3):453–6.
- Chung PHY, Wong KKY, Leung JL, Tam PKH, Chung KLY, Leung MWY, et al. Clinical and manometric evaluations of anorectal function in patients after transanal endorectal pull-through operation for Hirschsprung's disease: a multicentre study. *Surg Pract*. 2015;19(3):113–9.
- Nasr A, Langer JC. Evolution of the technique in the transanal pull-through for Hirschsprung's disease: effect on outcome. *J Pediatr Surg*. 2007;42(1):36–40.
- Gunnarsdottir A, Larsson L-T, Arnbjörnsson E. Transanal endorectal vs. Duhamel pull-through for Hirschsprung's disease. *Eur J Pediatr Surg*. 2010;20(04):242–6.

29. Chattopadhyay A, Patra R, Murulaiah M. Soave procedure for infants with Hirschsprung's disease. *Indian J Pediatr.* 2002;69(7):571–2.
30. Baraket O, Karray O, Ayed K, Baccar A, Moussa M. Hirschsprung's disease in adult treated by coloproctectomy and colo-anal anastomosis. *J Case Rep Stud.* 2016;4(2):210. <https://doi.org/10.15744/2348-9820.4.210>.
31. Tannuri ACA, Tannuri U, Romão RLP. Transanal endorectal pull-through in children with Hirschsprung's disease—technical refinements and comparison of results with the Duhamel procedure. *J Pediatr Surg.* 2009;44(4):767–72.
32. Albanese CT, Jennings RW, Smith B, Bratton B, Harrison MR. Perineal one-stage pull-through for Hirschsprung's disease. *J Pediatr Surg.* 1999;34(3):377–80.
33. Oh C, Lee S, Lee S-K, Seo J-M. Difference of postoperative stool frequency in Hirschsprung disease according to anastomosis level in a single-stage, laparoscopy-assisted transanal endorectal pull-through procedure. *Medicine.* 2016;95(14):e3092.
34. Till H, Heinrich M, Schuster T, Schweinitz DV. Is the anorectal sphincter damaged during a transanal endorectal pull-through (TERPT) for Hirschsprung's disease? A 3-dimensional, vector manometric investigation. *Eur J Pediatr Surg.* 2006;16(3):188–91.

Publisher's Note

Springer Nature remains neutral with regard to jurisdictional claims in published maps and institutional affiliations.

Submit your manuscript to a SpringerOpen[®] journal and benefit from:

- ▶ Convenient online submission
- ▶ Rigorous peer review
- ▶ Open access: articles freely available online
- ▶ High visibility within the field
- ▶ Retaining the copyright to your article

Submit your next manuscript at ▶ [springeropen.com](https://www.springeropen.com)
