

CASE REPORTS

Open Access



Persistent urogenital sinus with recto-vaginal fistula: the new variant in which the anus is normally positioned and literature review

Hikmet Zeytun^{*} , Ahmet Demez^{1b} and Bulent Hayri Ozokutan

Abstract

Background: Persistent urogenital sinus is a rare cloacal anomaly in which the urinary and genital tracts cannot be differentiated during embryonic development. However, the presence of concomitant recto-urogenital sinus or recto-vaginal fistula is much rarer. In the literature, only two cases with accompanying fistula have been presented so far.

Case presentation: We present the diagnosis and treatment management of a persistent urogenital sinus case with recto-vaginal fistula. We also aimed to reveal the difference between our patient, who is the 3rd case in the literature, and the other two and the described cloacal anomalies. By performing total urogenital sinus mobilization and fistula repair, the three systems were separated from each other, and both a functional and cosmetic appearance was obtained.

Conclusion: It should be kept in mind that there may be different variants other than the defined cloacal malformations. In patients with cloacal malformation, cystoscopy and rectoscopy should be performed to reveal the anatomy before reconstructive surgery in order to avoid any unexpected situation.

Keywords: Cloaca, Urogenital sinus, Dysgenesis, Fistula, Hydrocolpos

Background

The developmental mechanisms of malformations affecting the urogenital and anorectal systems are still under debate [1]. The urorectal septum divides the cloaca into two different systems, the urogenital and anorectal systems. These two systems are named differently based on the number and location of the perineal openings. In the presence of two perineal openings the urogenital and the anus, the possibilities include the persistent urogenital sinus (PUGS), the cloaca variant or the posterior cloacal variant [1, 2]. PUGS is a cloacal anomaly with an incidence of 6/100,000 [3]. This situation may occur as a result of high intrauterine androgen exposure, anorectal malformation, or an isolated form independently of both

[2]. In this article, we present a new variant of cloacal anomaly, a case of PUGS with a recto-vaginal fistula in which the anus is normally positioned.

Case presentation

Our case was born by cesarean section from the first pregnancy of a 23-year-old mother at the 36th gestational week, weighing 2300 g. The patient was referred to our clinic on the 4th day of delivery for the disorder of sexual development (DSD) and intraabdominal cystic mass. A 9 × 6 cm cystic structure with thick walls pressing on the bladder was reported in ultrasonography (Fig. 1a). On physical examination, there was a hypertrophic phallus with a single opening at the tip. The anus was seen in normal localization and diameter on the perineal examination. In addition, bilateral gonads were not palpable, and the scrotum was undeveloped (Fig. 1b).

Urinary drainage was observed from both the urogenital opening and anus during the abdominal examination.

*Correspondence: hzeytun333@gmail.com

Faculty of Medicine, Department of Pediatric Surgery, Gaziantep University, Gaziantep 27310, Turkey

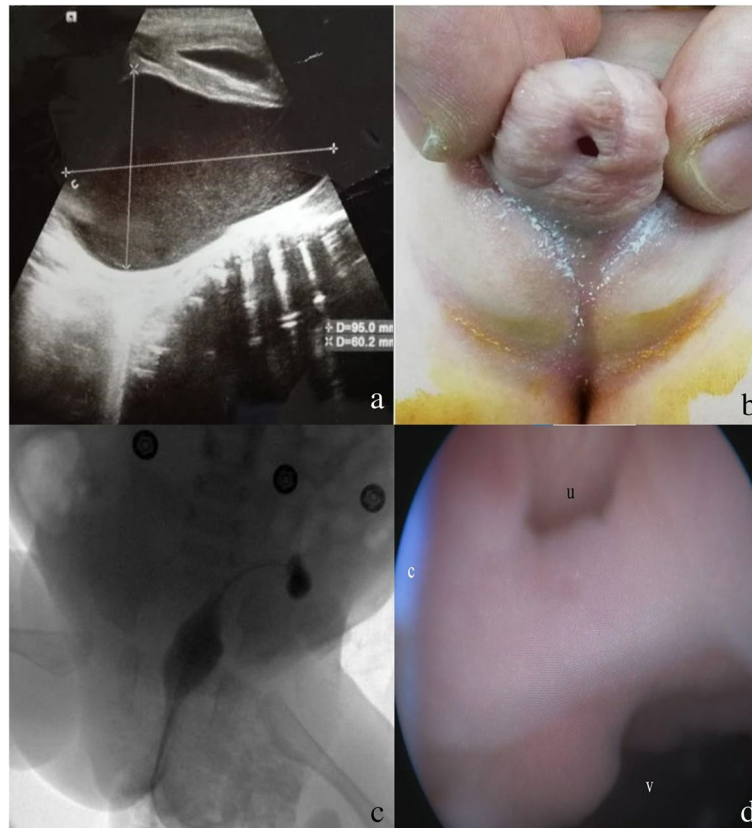


Fig. 1 **a** Hydrocolpos ultrasound image. **b** Hypertrophic phallus and external UGS meatus. **c** Genitography. **d** Rectoscopy image (c, catheter; v, vagina; u, urethra)

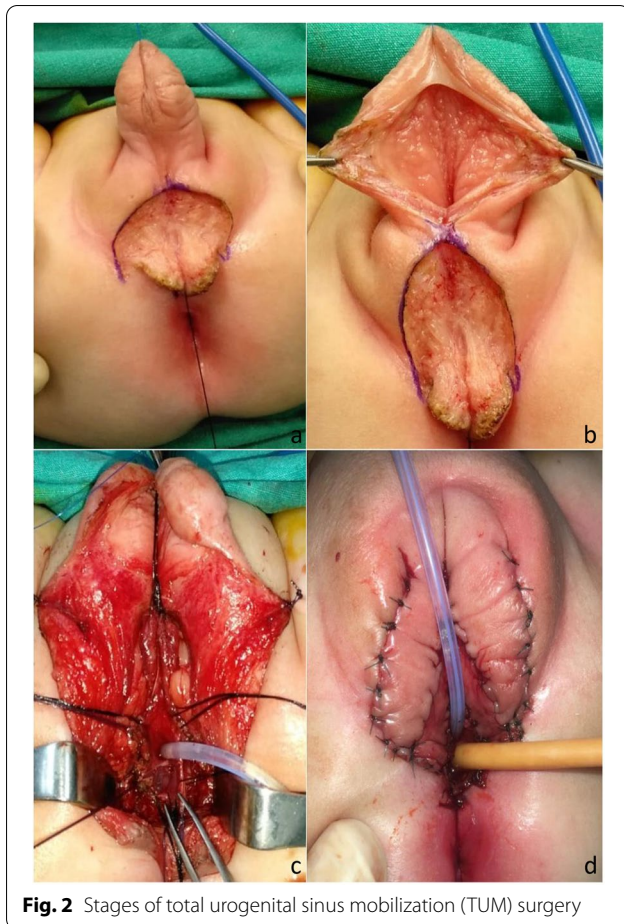
No abnormalities were detected in the hormone and electrolyte results of the patient with the 46-XX genotype. The bladder and vagina could not be visualized in the genitogram because the given contrast agent passed into the rectum (Fig. 1c). When entering through the urogenital opening with the cystoscope, stenosis which did not allow the passage was detected. Subsequently, the urethral opening was catheterized, and it was seen that the inserted catheter was in the rectum when rectoscopy was performed. During rectoscopy, the wide recto-vaginal fistula which the catheter passed, the dilated vagina, and just above it the urethra were seen (Fig. 1d). PUGS with recto-vaginal fistula was considered, and intra-abdominal cystic structure was interpreted as hydrocolpos. It was determined that the position of the anus was normal with anal stimulator examination, and its calibration was normal with an 11-mm Hegar dilator. Subsequently, the patient underwent a colostomy. Simultaneously, a Foley catheter was inserted into the bladder while a percutaneous catheter was placed in the uterine cavity. Total urogenital sinus

mobilization (TUM) and fistula repair were performed in the patient at the 6th month of life (Fig. 2). Proplem was not observed in the patient's controls. The presentation and photographing of this case were carried out with the written consent of the parents.

Discussion

Anorectal and urogenital malformations resulting from defective cloacal development can cause serious health problems in children [4]. The spectrum of anomalies associated with cloacal malformation likely results from the timing of the embryological developmental arrest [5]. The cloaca is a normal, transient embryologic structure in the 4- to 5-week embryo. By the sixth week, the urorectal septum divides the gastrointestinal system from the still combined urinary and genital systems. At 9 weeks, the urogenital septum divides UGS in the female fetus into the urinary and genital tract [1, 6, 7].

Depending on the disruptions in this developmental process, 6 variants of cloacal anomalies have been



described [1]. (1) *Cloacal dysgenesis*: The genitourinary and gastrointestinal tracts merge into a single common canal that terminates without opening to the perineum. (2) *Classic or persistent cloaca*: The common canal opens into the anterior perineum, where the urethra needs to be opened. (3) *Posterior cloaca*: The common canal with a single orifice in the region where the anus should be. (4) *Persistent urogenital sinus*: While the UGS opens to the anterior perineum where the urethra should be, the anus is positioned in its normal position (Fig. 3a). (5) *The cloacal variant*: As distinct from the persistent urogenital sinus, the anus is positioned immediately in front of the place that should be (Fig. 3b). (6) *Posterior cloaca variant*: The anus is in its normal location, but the urogenital sinus is located just in front of the anus (Fig. 3c) [1]. Our case shows that different cloacal anomalies can be seen apart from these definitions (Fig. 3d).

There are only two cases of the cloacal variant with recto-urogenital fistula reported by Patankart et al. [8] and Gupta et al. [9] in the literature. However, unlike

our case, it is stated that the anus is stenotic and anteriorly located in both cases. It is understood that both cases presented are cloacal variants with recto-vaginal fistula according to the classification described above. In our case, the anus was in normal diameter and localization (Fig. 2). Therefore, our case is the first and only case which PUGS and recto-vaginal fistula coexist in the literature.

Ultrasonography and MRI can be helpful in the diagnosis of such patients in the antenatal period. However, cystoscopy and rectoscopy are much more effective in investigating the common canal length and the presence of a fistula before surgery [1, 2]. In our case, since cystoscopy could not be performed due to UGS stenosis, recto-vaginal fistula could be detected by rectoscopy.

The PUGS is a common feature of a variety of congenital anomalies with XX-DSD due to high androgen exposure in fetal life [10]. A single urogenital opening and hypertrophic phallus can be observed in a female with CAH due to the effect of androgens. The urogenital opening is often located at the base of the phallus. In our case, there was a single opening at the tip of hypertrophic phallus (Fig. 2). In these cases, evaluation of the hormone and electrolyte profile is important for CAH. In the presence of findings suggestive of DSD, careful evaluation of the patient's hormone and electrolyte profile is recommended to avoid life-threatening situations.

Hydrocolpos is a common condition in cloacal anomalies due to both urinary retention and accumulation of vaginal secretions [7]. Hydronephrosis and fetal ascites may accompany hydrocolpos due to urine or meconium backflow [11, 12]. In our case, aspiration had applied due to fetal ascites in the antenatal period and grade II hydronephrosis was detected in the postnatal period. In these patients, the affected urinary and genital tract should be catheterized to relieve pressure. In addition, in the presence of a recto-vaginal or recto-urogenital fistula, a protective colostomy should be performed.

Although there are some anatomical differences between the different types of UGS, surgical techniques are similar [2]. Initially, the urethra was being completely separated from the vagina, the UGS was being opened into the perineum as the urethra, and the distal vagina was being created with a skin or mucosal flap [13–15]. In 1997, Peña [16] described TUM in which UGS was mobilized en-block. With TUM, both a good cosmetic appearance and a result in which all three systems are functional (Fig. 2). However, recto-vaginal closure was also possible in the same session.

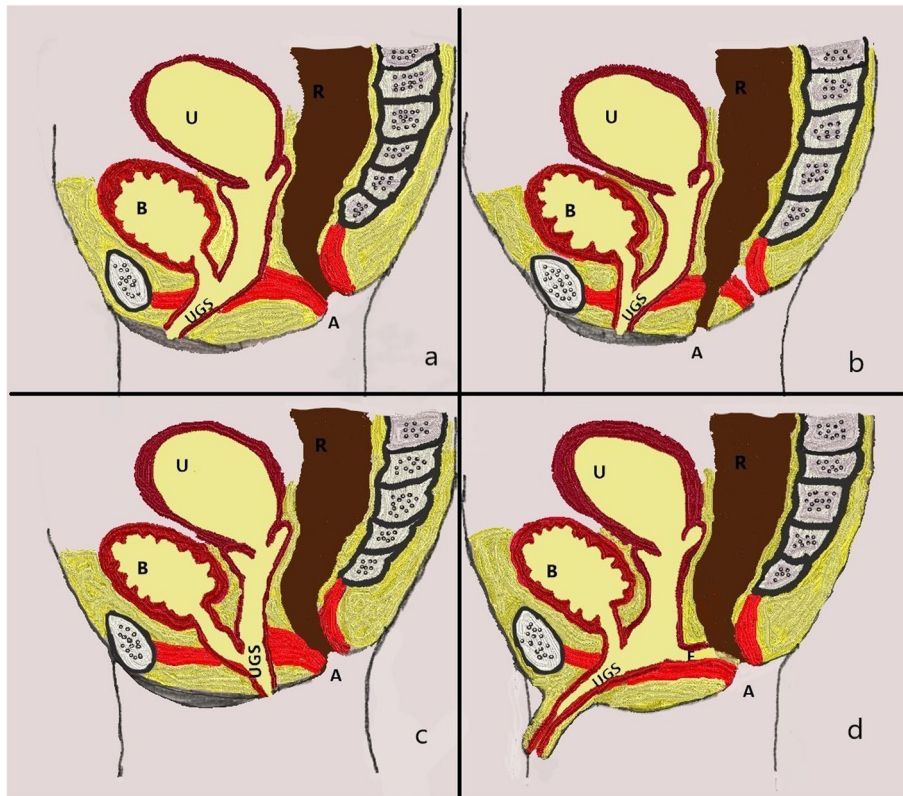


Fig. 3 a Persistent urogenital sinus. b The cloacal variant. c Posterior cloacal variant. d Persistent urogenital sinus with recto-vaginal fistula (A, anus; R, rectum; U, uterus; B, bladder; F, fistula; UGS, urogenital sinus)

Conclusion

As a result, it should be kept in mind that there may be different variants other than the defined cloacal malformations. Cystoscopy and rectoscopy are vital in investigating the common canal length and presence of a fistula. TUM appears to be a good option for the surgical treatment of PUGS with long common canal and rectovaginal fistula. However, close follow-up for urinary incontinence and retention is recommended after surgery. With a well-planned one-stage surgical approach, a good cosmetic appearance can be achieved in which all three systems are functional.

Acknowledgements

Not applicable

Authors' contributions

H.Z. wrote the article and performed the surgical operation. A.D. performed the surgical operation and took photographs. B.H.O. contributed to the critical review of the article. The authors read and approved the final manuscript.

Funding

The authors declared that this study has received no financial support.

Declarations

Ethics approval and consent to participate

The ethics committee the Faculty of Medicine, Gaziantep University, does not require ethical approval for reporting individual cases or case series.

Consent for publication

The presentation and photographing of this case were carried out with the written consent of the parents.

Competing interests

The authors declare that they have no competing interests.

Received: 24 April 2022 Accepted: 22 November 2022

Published online: 09 January 2023

References

1. Dannull KA, Browne LP, Meyers MZ. The spectrum of cloacal malformations: how to differentiate each entity prenatally with fetal MRI. *Pediatr Radiol.* 2019;49:387–98.
2. Ludwikowski BM, González R. The surgical correction of urogenital sinus in patients with DSD: 15 years after description of total urogenital mobilization in children. *Front Pediatr.* 2013;1:1–5.
3. Singh S, Singh P, Singh RJ. Persistent urogenital sinus. *J Anat Soc India.* 2010;59:242–4.
4. van der Putte SCJ. The development of the human ano-rectum. *Anat Rec Adv Integr Anat Evol Biol.* 2009;292:951–4.

5. Winkler NS, Kennedy AM, Woodward PJ. Cloacal malformation: embryology, anatomy, and prenatal imaging features. *J Ultrasound Med.* 2012;31:1843–55.
6. Gupta A, Bischoff A, Peña A, Runck LA, Guasch G. The great divide: septation and malformation of the cloaca, and its implications for surgeons. *Pediatr Surg Int.* 2014;30:1089–95.
7. Taori K, Krishnan V, Sharbidre KG, et al. Prenatal sonographic diagnosis of fetal persistent urogenital sinus with congenital hydrocolpos. *Ultrasound Obstet Gynecol.* 2010;36:641–3.
8. Patankar JZ, Vidyadhar M, Prabhakaran K, Bo L, Loh DL. Urogenital sinus, rectovaginal fistula, and an anterior stenosed anus - another cloacal variant: a case report. *Pediatr Surg Int.* 2004;20:556–8.
9. Gupta N, Bajaj S, Misra R. Persistent urogenital sinus with recto-urogenital sinus. *Astrocyte.* 2016;3:112.
10. Thomas D. The embryology of persistent cloaca and urogenital sinus malformations. *Asian J Androl.* 2020;22:124–8.
11. Manzella A, Borba FP. Hydrocolpos, uterus didelphys and septate vagina in association with ascites: antenatal sonographic detection. *J Ultrasound Med.* 1998;17:465–8.
12. Yamamichi T, Sakai T, Yoshida M, et al. Persistent cloaca with fetal ascites: clinical features and perinatal management. *Pediatr Surg Int.* 2022;38:1577–83.
13. Hendren WH. Surgical approach to intersex problems. *Semin Pediatr Surg.* 1998;7:8–18.
14. Gonzalez R, Fernandes ET. Single-stage feminization genitoplasty. *J Urol.* 1990;143:776–8.
15. Passerini-Glazel G. A new 1-stage procedure for clitorovaginoplasty in severely masculinized female pseudohermaprodites. *J Urol.* 1989;142:565–8.
16. Peña A. Total urogenital mobilization - an easier way to repair cloacas. *J Pediatr Surg.* 1997;32:263–8.

Publisher's note

Springer Nature remains neutral with regard to jurisdictional claims in published maps and institutional affiliations.

Submit your manuscript to a SpringerOpen[®] journal and benefit from:

- Convenient online submission
- Rigorous peer review
- Open access: articles freely available online
- High visibility within the field
- Retaining the copyright to your article

Submit your next manuscript at ► [springeropen.com](https://www.springeropen.com)
