

CASE REPORTS

Open Access



Delayed presentation of isolated female epispadias with urinary incontinence: a case report

Adewale Olaotan Oyinloye^{1*} , Samuel Wabada², Auwal Mohammed Abubakar¹ and Christopher Uruku Rikin¹

Abstract

Background: Female epispadias is a rare congenital anomaly, with a quoted incidence of 1 in 480,000. These patients present with urinary incontinence and varying degrees of external genitalia abnormality. This report presents the delayed presentation and management of a 14-year-old female with urinary incontinence due to isolated epispadias.

Case presentation: This is the case report of a 14-year-old female with urinary incontinence noticed since infancy. Examination of the genitalia revealed a bifid clitoris, depressed mons pubis, underdeveloped labia, patulous urethral opening, and normal vagina. She had surgical repair of the anomaly and has subsequently achieved continence. She has been continent in the last 4 1/2 years of follow-up and is now married with a 1-year-old child.

Conclusion: Female epispadias is a rare but often missed cause of incontinence. A high index of suspicion and careful genital examination will help in identifying this anomaly. Surgical correction achieves satisfactory outcome as regards continence and cleanliness. Long-term follow-up is essential.

Keywords: Female epispadias, Urinary incontinence, Reconstruction

Background

Female epispadias is a very rare congenital anomaly, with a quoted incidence of 1 in 480,000 in literature [1]. These patients usually present with urinary incontinence and varying degrees of abnormality in the appearance of the external genitalia.

The severity of external genitalia abnormality ranges from a patulous urethral orifice, dorsal urethral splitting along most of its length, to the most severe cases which involve the entire length of the urethra and bladder neck, rendering the sphincteric mechanism incompetent [2, 3]. Milder forms are rare and are usually not noticed due to the absence of incontinence in these children [4]. The condition may remain undiagnosed until parents

observe that the child is unable to achieve toilet training [1]. We report the delayed presentation and management of isolated female epispadias in a 14-year-old girl that presented at our hospital.

Case report

A 14-year-old female presented with urinary incontinence noticed since early childhood, with persistent urine soilage of underwear. She however feels the urge to micturate voluntarily. There was a history suggestive of recurrent urinary tract infection, but no history of trauma. There were no adverse events during pregnancy and she had normal developmental milestones. She is the last of 14 children by the mother, and there was no similar complaint among other members of the family. She had presented to various health centers, where parents were reassured that the child will “outgrow” the symptom with time.

Examination at presentation revealed a bifid clitoris, depressed glabrous mons, underdeveloped labia minora,

*Correspondence: walehoneyville@yahoo.com

¹ Division of Pediatric Surgery, Department of Surgery, Federal Medical Center, Yola, Adamawa State, Nigeria
Full list of author information is available at the end of the article

and a patulous urethral orifice (Fig. 1). The vaginal introitus appeared normal. A diagnosis of isolated female epispatias was made. Her body weight at presentation was 43 kg and her blood pressure was 100/70 mmHg.

Haemogram and serum electrolytes were within normal limits. Urine culture yielded growth of *Klebsiella* species, sensitive to quinolones. Micturating cystourethrogram revealed a normal capacity bladder with grade I left vesicoureteral reflux (VUR) and small pubic symphyseal diastasis (Fig. 2). There was no renal or upper tract anomaly on ultrasonography.

She was optimized and had urogenital reconstruction using a single-stage perineal reconstruction technique [5]. The basic steps in the surgery include lithotomy positioning of the patient, application of stay sutures and Foleys catheter, creation of a vertical mons incision extended laterally to both sides of the urethral opening, dissection and mobilization of urethra towards the bladder neck, denudation of a short mucosal strip (10 mm) from one half of the urethral plate towards the bladder

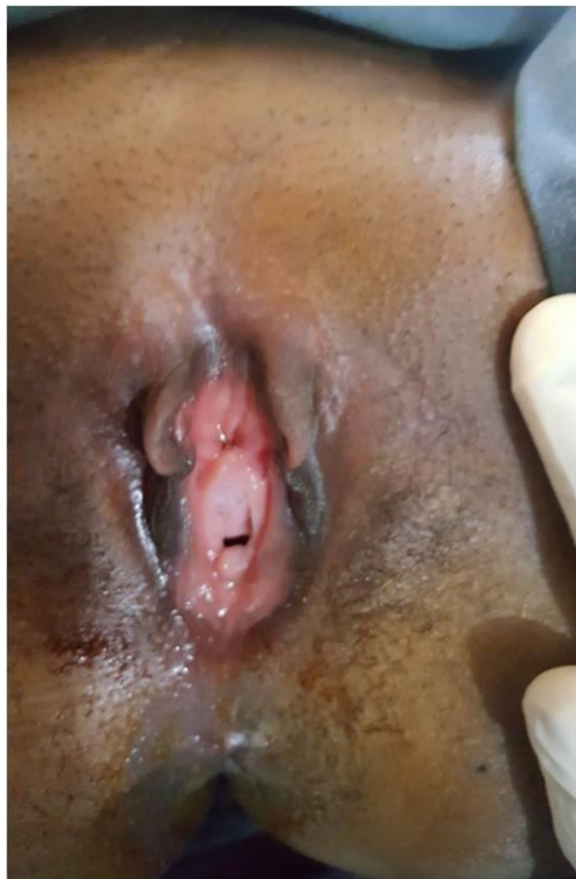

Fig. 1 Clinical photograph showing the depressed mons, bifid clitoris, underdeveloped labia, patulous urethral opening, and normal vagina

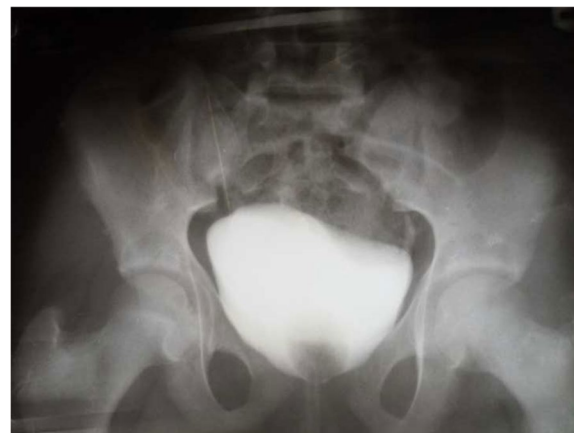

Fig. 2 Micturating cystourethrogram

neck, double-breasted urethroplasty, sphincteroplasty, clitoroplasty, labioplasty, and monsplasty (Fig. 3A–D). The urethral catheter was left in situ for 14 days. She did well post-operatively (Fig. 4), achieved continence, and has remained dry up to the last follow-up visit. She is currently 4 ½ years post-surgery and is fully continent of urine. She is now married and has delivered a 1-year-old female child (per vaginam).

Discussion

The Davis classification [3] describes 3° of female epispatias; the mildest form being a patulous urethral opening, the intermediate form in which the urethra is dorsally split along most of its length, and the severest form characterized by cleft involving the entire length of the urethra and the sphincteric mechanism with associated incontinence [1, 3]. The examination of the external genitalia may reveal a bifid clitoris, depressed mons covered by a smooth, glabrous area of skin and poorly developed labia minora. The pubic symphysis is usually closed or may be represented by a narrow fibrous band. The vagina and internal genitalia are however usually normal [1, 3].

The incidence of VUR is reported to be between 30 and 75%, and a grade I reflux was observed in our patient. Reflux occurs because the ureterovesical junction is inherently deficient, and the ureter is often laterally placed in the bladder with a straight course [2, 6].

The incontinence seen in female epispatias varies from continuous dribbling without bladder filling, to episodes of daytime stress incontinence. Often, the bladder capacity is reduced and the bladder wall thinned out as a consequence of lack of filling [1, 7]. Our patient had more of daytime stress incontinence, which may account for the normal bladder capacity observed during the radiological evaluation.

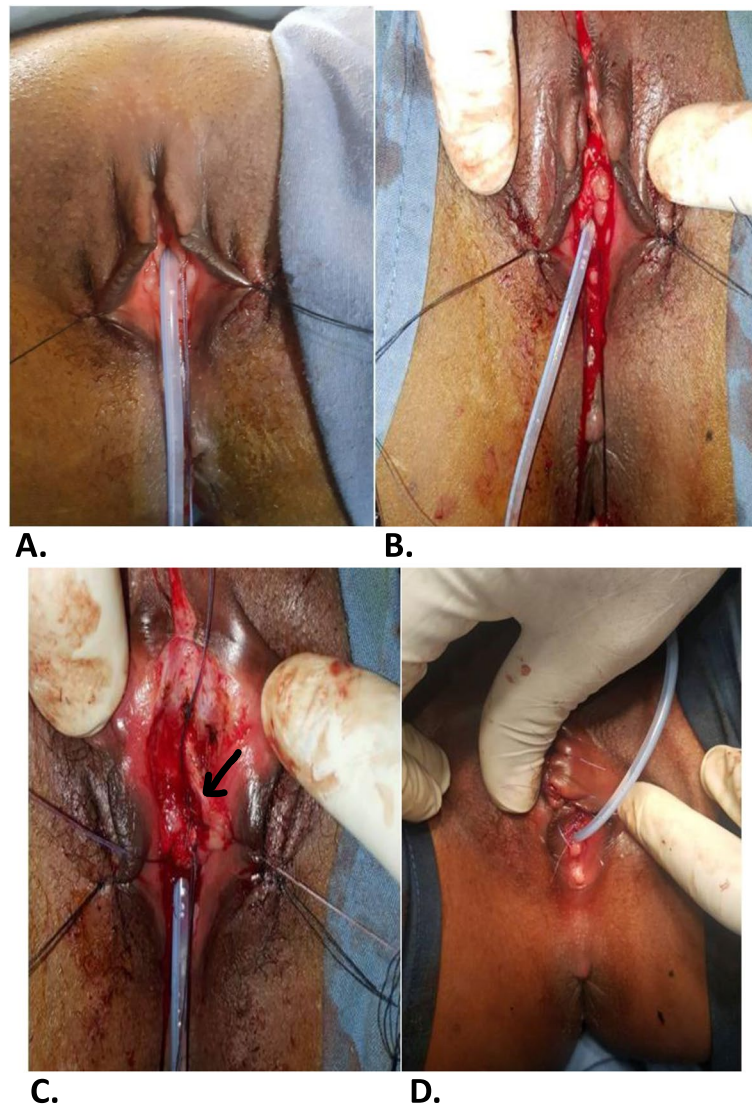


Fig. 3 **A** Size 10 Silastic Foley's catheter and stay sutures in place. **B** Vertical mons incision extended towards both sides of the urethral plate. **C** Two layered urethral reconstruction over the Foley's catheter (marker on the denuded left urethral half to be sutured over the first layer urethroplasty in a double-breasted manner). **D** Immediate post-operative picture

The goal of surgery is to achieve continence, preserve the upper tracts, and reconstruct a functional and cosmetically acceptable external genitalia [1]. Various techniques for urogenital reconstruction and continence have been described. These include staged reconstruction, transvaginal plication of the urethra and bladder neck, muscle transplantation, urethral twisting, cauterization of the urethra, bladder flap, Marshall-Marchetti vesicourethral suspension, modified needle suspension, single-stage perineal urethroplasty, and bladder neck plication via a perineal approach [1, 2, 4, 5, 8–13]. A single-stage perineal urethroplasty beginning with an inverted “Y” incision was used in this patient, with good outcome [5].

The technique improved the urethral resistance, which in addition to good bladder capacity and intact bladder neck, is an important factor for continence. The continence rate following surgical reconstruction of female epispadias varies from 67 to 87.5% in literature [1, 14].

The delayed presentation in this patient may be due to a combination of the severity of the incontinence, repeated misdiagnosis, and social stigma associated with incontinence. Our patient achieved urinary continence with an overall improvement in her hygiene, self-esteem, and social interaction. The parental satisfaction following surgical intervention was also significant. The absence of facilities for urethroscopy and urodynamic studies

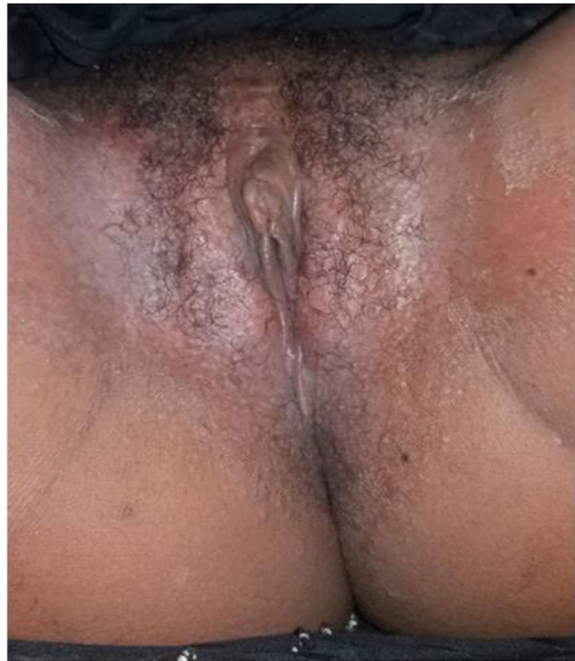


Fig. 4 Clinical picture at 6th post-operative week

is one of the challenges encountered in the care of this patient.

Conclusion

Female epispadias is a rare but often missed cause of incontinence. A high index of suspicion and careful genital examination will help in identifying this anomaly. Surgical correction achieves satisfactory outcome as regards continence and cleanliness. Long-term follow-up is essential.

Abbreviation

VUR: Vesico-ureteric reflux.

Acknowledgements

Not applicable.

Authors' contributions

AOO and WS, conceptualized and designed the study. AOO, WS, AMA CUR contributed to case summarization and literature search and initial draft. All authors read and approved the final manuscript.

Funding

There was no funding for this study.

Availability of data and materials

Available upon request.

Declarations

Ethics approval and consent to participate

This research was done in accordance with the ethical standards of the Federal Medical Centre, Yola and national health research committee and with the 1964 Helsinki declaration and its later amendments. Informed consent was obtained from the parents of the patient for this study.

Consent for publication

Written consent for publication was obtained from the parents of the patient.

Competing interests

The authors declare that they have no competing interests.

Author details

¹Division of Pediatric Surgery, Department of Surgery, Federal Medical Center, Yola, Adamawa State, Nigeria. ²Paediatric Surgery Unit, Department of Surgery, University of Maiduguri Teaching Hospital, Maiduguri, Borno State, Nigeria.

Received: 7 December 2021 Accepted: 3 August 2022

Published online: 12 September 2022

References

- Gearhart JP, Mathew R. Exstrophy-Epispadias complex. In: Campbell-Walsh Urology. 10th ed. AJ Wein, LR Kavoussi, AC Novick et al. Philadelphia; Saunders 2012;4,124,p 3325-3378.e5.
- Gearhart JP. Complete genitourinary reconstruction in female epispadias. *J Urol.* 1993;149:1010.
- Davis M. Epispadias in females and its surgical treatment. *Surg Gynaecol Obstet.* 1928;47:680–96.
- Mollard P, Basset T, Mure PY. Female epispadias. *J Urol.* 1997;158:1543–6.
- Bhat AL, Bhat M, Sharma R, Saxeno G. Single stage perineal urethroplasty for continence in female epispadias: A preliminary report. *Urology.* 2008;72:300–3.
- Kramer SA, Keralis PP. Surgical correction of female epispadias. *Eur Urol.* 1982;8(6):321–4. <https://doi.org/10.1159/000473547>.
- Krishna Shetty MV, Bhaskaran A, Sen TK. Female epispadias. *Afr J Paediatr Surg.* 2011;8:215–7.
- Tom de Jong PVM, Dik P, Kiln AJ. Female epispadias repair: a new 1-stage technique. *J Urol.* 2000;164:492–4.
- Manzoni G, Ransley P. Primary surgical intervention for female epispadias. *J Paediatr Urol.* 2007;3:573.
- Cheikhelard A, Aigrain Y, Lottmann H, et al. Female epispadias management; perineal urethrocervicoplasty versus classical Young-Dees procedure. *J Urol.* 2009;182:1807.
- Lazarus J, van den Heever A, Kortekaas B, et al. Female epispadias managed by bladder neck plication via a perineal approach. *J Paediatr Urol.* 2012;8:244.
- Macedo A, de la Cruz ML, Trivlato R, Garrone G, et al. Complete female epispadias: The case for perineal approach. *J Paediatr Urol.* 2015. <https://doi.org/10.1016/j.jpuro.2014.08.013>.
- Alyami F, Fernandez N, Lee L, Metcalfe P, Lorenzo A, Salle JP. Long-term follow-up after traditional versus modified perineal approach in the management of female epispadias. *J Paediatr Urol.* 2017;13(5):497.e1–5.
- Hanna MK, Williams DL. Genital function in males with exstrophy and epispadias. *Br J Urol.* 1972;44:1969.

Publisher's Note

Springer Nature remains neutral with regard to jurisdictional claims in published maps and institutional affiliations.