

ORIGINAL RESEARCH

Open Access



# Distinct presentations and management of hernia of the umbilical cord: 15 years' experience in a tertiary hospital

Yasir S. Jamal<sup>1\*</sup> , Mazen O. Kurdi<sup>1</sup> , Ettedal A. Aljahdali<sup>2</sup> , Samera F. AlBasri<sup>2</sup> and Abdullah Y. Jamal<sup>1</sup>

## Abstract

**Background:** Hernia of the umbilical cord (HUC) is an uncommon type of abdominal wall defect characterized by a hernia of the midgut into the proximal section of the umbilical cord. This is occasionally coupled with other congenital abnormalities. This is frequently misdiagnosed and referred to as “omphalocele minor.” In certain cases, unintentional cord clamping causes iatrogenic intestinal harm. The purpose of this retrospective study is to highlight various aspects of the HUC therapy in 30 patients with typical and unusual presentations in a tertiary care facility as well as intraoperative findings and associated abnormalities.

**Methods:** Thirty neonates (21 males and 9 females) with usual and unusual presentations of HUC diagnosed and treated at the King Abdelaziz University Hospital, Jeddah, Saudi Arabia, over 15 years period from 2005 to 2020.

**Results:** Out of 30 cases included, 17 patients were reducible with simple classical HUC repair. While 13 patients had different presentations, six cases presented with irreducible content due to variable reasons, four cases presented with patent vitellointestinal duct (PVID), 2 cases presented with intestinal obstruction, and one case presented late with epithelialized HUC sac.

**Conclusions:** Attention to HUC should be paid by obstetric professionals in order not to miss it on antenatal ultrasound and careful umbilical cord examination at delivery to avoid clamping of visceral content if present in HUC.

**Keywords:** Associated anomalies, Bowel obstruction, Hernia of the umbilical cord, Irreducibility, Management, Patent omphalomesenteric duct

## Background

The umbilicus is a place for a number of embryopathies, including the urachus, blood vessels, midgut herniation, anterior abdominal wall abnormalities, and congenital cysts. During embryological development, the anterior abdominal wall is composed of caudal, cephalic, and two lateral folds; failure of four folds to meet in midline results in the formation of an umbilical defect [1–3]. Abdominal wall abnormalities encompass a wide range

of congenital malformations that range from fatal limb-body wall syndrome to benign hernia of the umbilical cord (HUC) [4]. The incidence of HUC is predicted to be 1–2.5 in 5000 live birth [5]. HUC is regarded to be benign with good outcomes, and their isolated occurrence has not been linked to other chromosomal abnormalities [6].

During the first 10–12 weeks of intrauterine life, the fetal intestine returns to the abdominal cavity because the umbilical ring does not seal. At this point, if a tiny portion of the intestine contents is unable to entirely return to the abdomen and distinct parts of the intestines stay in the extracelomic cavity in the cord, it will manifest at birth as a congenital hernia into the umbilical cord [4]. The defect solely affects the midgut, as opposed to other

\*Correspondence: Profyasar.jamal.2020@gmail.com

<sup>1</sup> Department Of Pediatric Surgery, Faculty of Medicine, King Abdulaziz University, P.O. Box 80215, Jeddah 21589, Saudi Arabia  
Full list of author information is available at the end of the article

abdominal wall abnormalities, which include abdominal viscera herniation through an anterior abdominal wall defect [2]. Omphalocele minor is frequently misdiagnosed as HUC. Unlike gastroschisis and omphaloceles, HUC has a complete umbilical ring, intact abdominal wall, a sac made up of inner peritoneal and outer amnion lining, and midgut contents. From the abdominal wall to the sac neck, a distinct cuff of the skin can be recognized. HUC often manifests as an asymmetrical globular swelling at the abdominal connection of the cord that extends into its substance. When there is a constriction between enlargement and the belly, a major accident can occur, as in a case described by Victor Bonney et al., where a practitioner removed the hernial sac and its intestinal contents, which included the small intestine, during cord ligation and division of the cord [7].

Umbilical abnormality can be diagnosed with certainty after delivery, but antenatal ultrasonography (USG), amniocentesis, karyotyping, and amniotic fluid alpha-fetoprotein (AFP) can be helpful in determining these abnormalities as HUC, omphalocele, and cord teratoma [4]. The complications accompanying HUC include intestinal malrotation, obstruction of the bowel, atresia, and trauma to the bowel caused by accidental umbilical cord clamping [3].

Owing to a lack of HUC awareness, it is usually underreported and misdiagnosed, with seldom information in literature. The aim of this study was to present an experience in the management of 30 newborns of variable usual and unusual presentations of HUC and increasing awareness among the obstetrical professional and pediatric surgeons to stress upon diagnosis essential, operative management, and associated anomalies of such type of umbilical abnormality.

## Methods

This retrospective study was done on neonates who presented with HUC and attended the outpatient and emergency sections of the Pediatric Surgery Department, King Abdulaziz University Hospital, Jeddah, Saudi Arabia, during 15 years period from January 2005 to December 2020. The Institutional Review Board of King Abdulaziz University, Jeddah, Saudi Arabia, approved the research.

*Inclusion criteria* were patients with umbilical ring intact; the presence of anterior abdominal wall and presence of sac contains a peritoneum inner layer and amnion outer layer, with sac contents of various midgut intestinal loop.

*Exclusion criteria* were cases of omphalocele and gastroschisis or other abdominal wall defects.

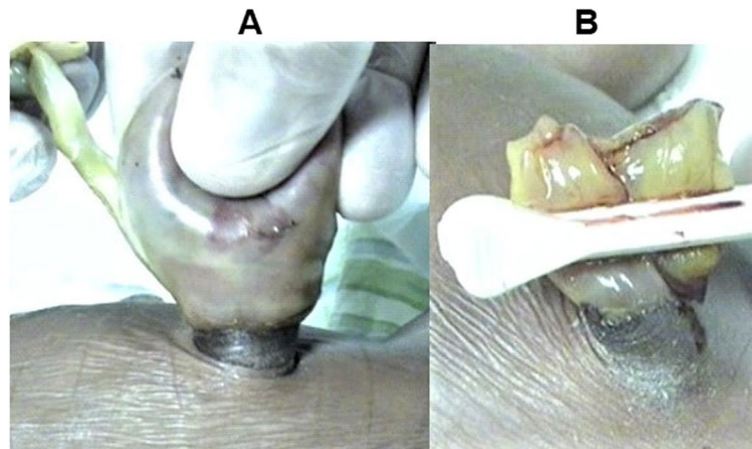
Thirty cases of HUC (21 males and 9 females) were diagnosed with essential criteria of the presence of an umbilical defect of less than 4 cm with projecting cuff of

the skin at the base of umbilical ring and the presence of midgut loops in the sac at the proximal part of the umbilical cord or ruptured sac with patent vitellointestinal duct (PVID) or prolapsed none reducible bowel; accordingly, patients were managed at the King Abdelaziz University Hospital. The antenatal and postnatal investigations, associated anomalies, and different methods of reduction as well as their surgical repair were reviewed and recorded from patient's hospital database sheets. The obstetric team reviewed 18 antenatal ultrasonography which were available with no definite signs of the presence of any visceral contents at a proximal end of the cord at the time of examination and reviewed the antenatal obstetrical history and pregnancies outcome. All of the cases were delivered near term ranging between 34 and 38 weeks. No antenatal amniocentesis, karyotyping, or amniotic fluid AFP were done.

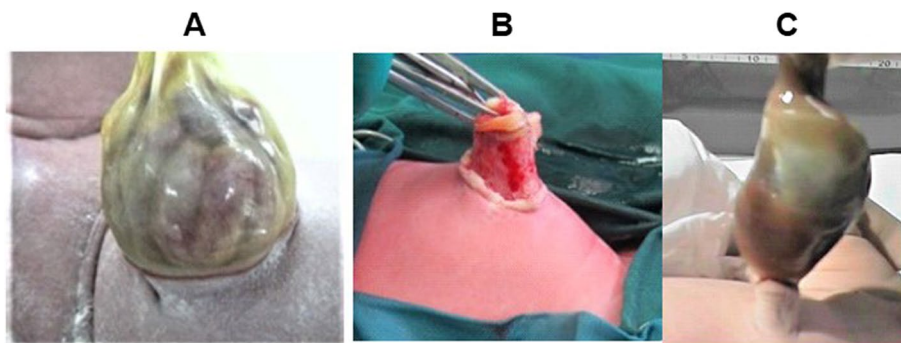
## Results

Thirty neonates were included in this study; of them, 17 patients had simple classical reducible HUC; of the 14 cases, including a patient with Edward syndrome, contents were easy to reduce and treated with simple manual reduction of contents and sac closure with the application of proximal umbilical clamp (Fig. 1A, B) or ligation with 3/0 vicryl. The other 3 cases of simple HUC needed open surgical reduction, two had open surgical reduction with defect repair and umbilicoplasty due to broad base in one (Fig. 2A), and in the other one due long neck at HUC base (Fig. 2B) where on suturing of the sac proximally, a swelling remains projecting equivalent to umbilical hernia, and 2nd stage surgical repair and umbilicoplasty were done. While in the 3rd case upon trial of reduction, the hemorrhagic fluid was developed in the sac (Fig. 2C); then, under sedation, the surgical exploration of the sac was done with the finding of blood clots, and only then the application of the umbilical clamp proximally was sufficient.

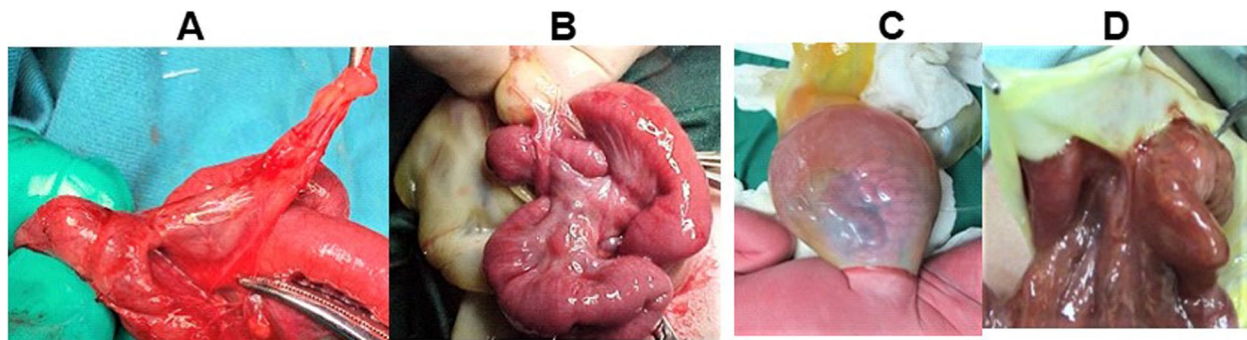
Meanwhile, the other 13 patients had different presentations. Six cases were presented by an irreducible content, all needed surgical interventions (repair +/- umbilicoplasty). The intraoperative finding was as follows: the irreducibility in one patient was due to adhesions fixing Meckel's diverticulum and adjacent ilium to the hernial sac (Fig. 3A) that needed surgical interventions, adhesion release and excision of Meckel's diverticulum, and then repair and umbilicoplasty. Another patient irreducibility was due to fibrous adhesive bands in the sac intermingling loops of the ilium in the umbilical hernial sac preventing the loop to be reduced (Fig. 3B) (needed surgical interventions by release of adhesive bands, repair, and umbilicoplasty). Another three patient's irreducibility were due to trapping of the



**Fig. 1** Usual hernia of umbilical cord (A) that was easy to reduce the content. Treated with simple manual reduction of the contents and closure of the sac with application of proximal umbilical clamp (B)



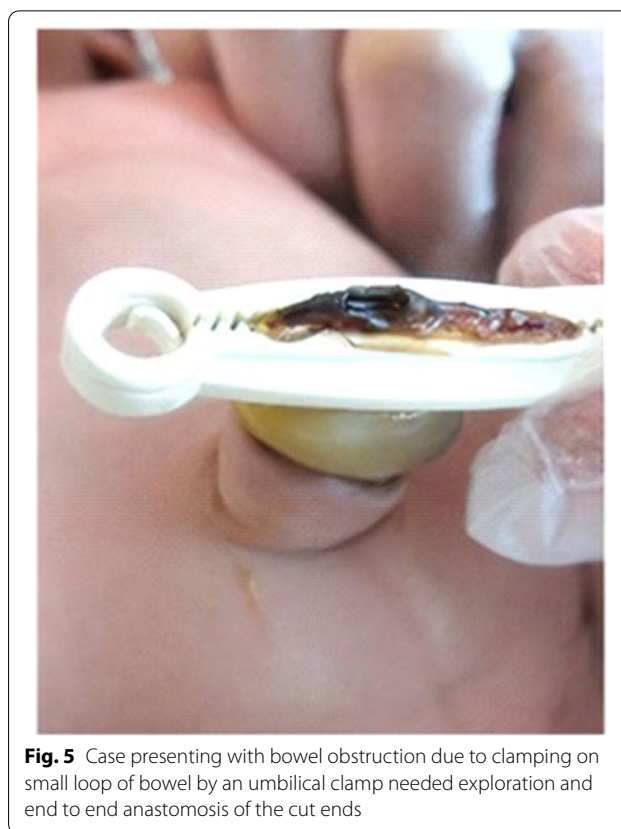
**Fig. 2** Usual hernia of the umbilical cord (HUC) needed surgical intervention: **A** needed surgical repair due to broad base; **B** needed surgical repair due to long neck of skin at the base of HUC, on suturing of proximal end of the sac, long umbilical hernia like swelling remains projecting, had stage surgical repair, **C** hemorrhagic fluid seen in the sac upon manual reduction then under sedation, surgical exploration of the sac was done, revealed clotted blood content only then clamping of the neck of the sac was sufficient



**Fig. 3** Hernia of the umbilical cord (HUC) with irreducibility due to **A** adhesions fixing Meckel's diverticulum and adjacent ileum to hernial sac, needed release of the adhesions and excision of Meckel's diverticulum. **B** Fibrous adhesive bands in the sac intermingling loops of ileum preventing the loops to be reduced, needed surgical interventions (release the adhesive bands). **C** Ileal loops trapped in the sac by peritoneal septum at umbilical ring (adhering to narrow ring), needed exploration of the sac and dilatation of sac neck and reduction of content, repair, and umbilicoplasty. **D** Sliding hernia where loops of ileum forming the sac wall needed to be dissected from the sac to be reduced

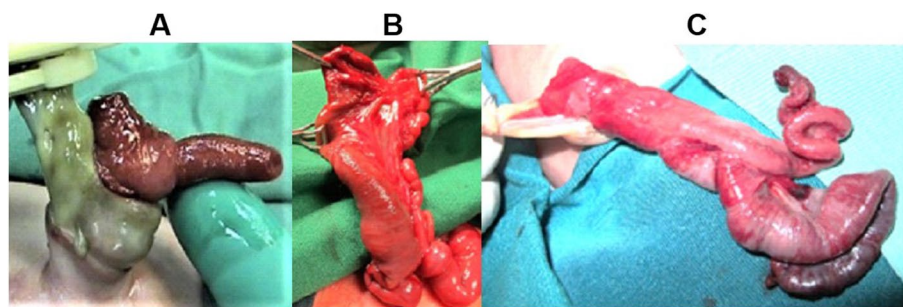
ileal loops in the sac by a peritoneal septum at the umbilical ring or adherence to narrow ring (Fig. 3C), which needed sac exploration and dilatation of the sac neck and reduction of content and then repair and umbilicoplasty; the last patient of irreducible HUC (Fig. 3D) was due to sliding hernia, where the loops of ilium forming part of the wall of sac were needed to be dissected from the sac to be reduced with repair and umbilicoplasty. There were four cases of HUC with patent vitellointestinal duct (Fig. 4A); one of them was associated with ileal atresia distal to PVID, all treated as the standard surgical treatment of PVID by dissection from the umbilical ring and excision of PVID and restoring midgut continuity; the ileal atresia was treated with resection and anastomosis and then concluded with umbilicoplasty. Two cases were presented with intestinal obstruction; one was due HUC-associated multiple ileal atresia and micro-colon, and ileostomy was created after resection and anastomosis of the atretic segment (Fig. 4B). Another patient with intestinal obstruction was due to clamping on a small loop of bowel by an umbilical clamp that led to intestinal obstruction that needs an end-to-end anastomosis of cut ends (Fig. 5). The last case attended was at the age of 4 weeks with HUC (Fig. 6A), but the father refused any procedure and re-attended at the age of 3 months with epithelialized sac of HUC (Fig. 6 B), which was presented as large broad umbilical defect with redundant skin, treated by Mayo's repair and umbilicoplasty.

The obstetricians review the obstetrical history, in all the 30 patients with a variable presentation of HUC which was irrelevant on pregnancy course and outcome; on the other hand, the non-surgical and surgical outcome were satisfactory except for the major fatal congenital abnormalities in the two patients: one was with Edward syndrome, and the other one was transferred from another hospital in bad general condition

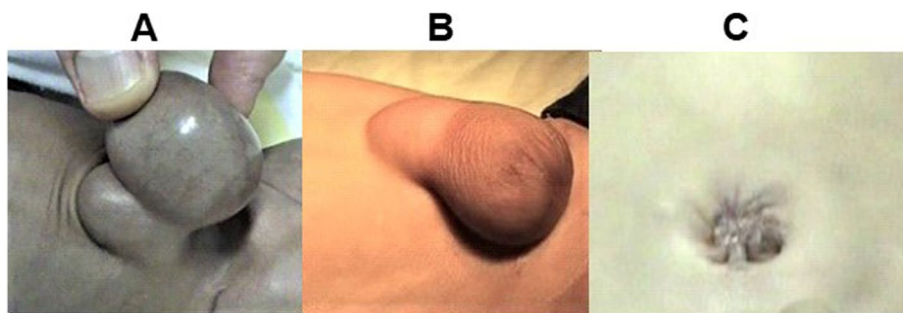


**Fig. 5** Case presenting with bowel obstruction due to clamping on small loop of bowel by an umbilical clamp needed exploration and end to end anastomosis of the cut ends

with severe respiratory distress syndrome, multiple congenital anomalies, dysmorphic facial features, hypospadias, brain leukodystrophy, and short non-rotated intestine with ileocecal perforation (Fig. 4C). Another two of the HUC patients had an associated non-fatal congenital abnormalities in the form of the ileal atresia with PVID in one (Fig. 4A) and the other HUC with



**Fig. 4** Hernia of the umbilical cord (HUC) associated with other abnormalities: **A** HUC with patent vitellointestinal duct (PVID) and ileal atresia treated as the standard surgical excision and repair of PVID; ileal atresia was treated with resection and anastomosis. **B** HUC with intestinal obstruction due to multiple ileal atresia, and microcolon, ileostomy was created after resection and anastomosis of the ends of atretic segments. **C** Rupture of HUC exploration under general anesthesia with finding of bowel non-rotation, short bowel, and ileocecal perforation, treated with repair of the perforation and colostomy



**Fig. 6** Case was seen at age 4 weeks (A), disappeared to represent at age of 3 months with epithelialized hernia of umbilical cord (HUC) (B), treated by Mayo's repair and umbilicoplasty (C)

multiple ileal atresia (Fig. 4B). Table 1 summarizes the 30 cases of hernia of the umbilical cord.

**Discussion**

Hernia of the umbilical cord can be defined as a simple midgut failure to return from the umbilical celom to the peritoneal cavity at 10–12 weeks of gestation, so the defect has solely midgut unlike the other abdominal wall defects which can be defined as herniation of the abdominal viscera through an anterior abdominal wall defect. HUC described as <4 cm in diameter has only midgut but never liver and covered by a membrane with a normal abdominal wall above the defect [8]. All patients involved in this study were fulfilling the HUC criteria. The majority of patients in this study had a diameter of 2–3 cm; only one patient had a diameter of 3.5 cm. None of the cases involved in this study had contents other than the midgut, but it is worth to stress upon the presence of projecting cuff of the skin from the umbilical ring with the sac at the cord proximal end displacing Warton jelly as essential criteria of HUC.

HUC was first reported in researches by Hempel-Jorgensen in 1929, and he reported two cases in a family of this entity and had coined the term familial congenital

umbilical hernia [9]. After that, little case reports were published clearly describing this entity [10–12]. Proper antenatal diagnosis by ultrasound, amniocentesis, karyotyping, and amniotic fluid AFP needs to be done to differentiate between abdominal wall defects and other umbilical cord abnormalities. Moreover, this research did not record cases diagnosed by antenatal USG. Stanley et al. [13] used antenatal USG to differentiate omphalocele from HUC by the presence of the liver in the sac. Achiron et al. [10] reported that HUC happened at early embryological stage and diagnosed at early second trimester on antenatal USG. Sherer and Dar [14] diagnosed hematoma of the umbilical cord or excessive Wharton's jelly after his antenatal USG observation as well as using karyotype, amniotic fluid, and AFP data. Elevated AFP in both amniotic fluid and maternal serum and raised amniotic fluid acetylcholinesterase associated with abdominal wall defects when myelomeningocele is absent [15]. So, the existence of normal amniotic fluid, AFP, normal appearing abdominal umbilical cord insertion covered by echogenic non-membranous covering, with semisolid, semi-cystic lesion distal to insertion point, which at times may reveal peristalsis movement, and lack of associated anomalies can support HUC diagnosis. Meanwhile, pure

**Table 1** Summary of the 30 cases of hernia of the umbilical cord (HUC)

14 HUC simple manual reduction	4 HUC WITH PVID
○ 12 HUC clamped	○ 1 of these 4 HUC associated with none rotation, short bowel and perforated distal ileum
○ 2 HUC ligated with 3/0 vicryl	6 HUC with non-reducible contents
3 HUC needed surgical intervention due to:	○ 1 HUC with Mikel's diverticulum and adhesions
○ 1 HUC with broad base	○ 3 HUC with peritoneal septum and narrow communication
○ 1 HUC with long neck	○ 1 HUC with fibrous bands in the sac trapping loops of the ileum
○ 1 HUC with hemorrhagic fluid in the sac	○ 1 HUC with sliding hernia
	2 HUC with intestinal obstruction
	○ 1 due to ileal atresia had ileostomy
	○ 1 due to application of umbilical clamp on the intestine in HUC
	1 HUC late presentation
	Patient with epithelialized hernia of the umbilical cord

omphaloceles, a more common lesion, have different prenatal ultrasonographic characteristics, as a wider base or stalk covered by a thin membrane and associated elevated amniotic fluid AFP, as well as a well-established high frequency of associated fetal chromosomal and structural anomalies [15]. Prenatal diagnosis, as well as a thorough clinical evaluation, is critical in preventing intestinal injury during cord clamping during birth [16]. The more recent obstetric literature reported no benefit of delivering these babies by cesarian Sect [17–19]. In this study, male preponderance (21 cases, 70%) was present which was in accordance with previous studies [9, 11].

There are four varieties of HUC: type 1 is a simple hernia into the cord with no accompanying consequences, type 2 is associated with intestinal obstruction, type 3 is linked with mucosal prolapse, and type 4 is associated with evisceration [20, 21]. Other related defects including the intestine atresia, persistent cloaca, Meckel's diverticulum, small bowel syndrome, vitelointestinal duct persistence, and stenosis, glaucoma, congenital heart disease, and cleft lip and palate are rarely associated with HUC [22]. There have been no reports of underlying genetic abnormalities associated with HUC up to now [23].

Our experience in the management of 30 neonates with HUC showed that the majority of patients (17 cases) had a simple classical HUC that was managed with full content reduction and non-surgical closure of defect by applying the umbilical clamp or vicryl tie at the base of HUC except for 3 of these usual cases where additional minor surgical intervention was needed. On the other hand, 13 patients presented with complicated unusual presentations and need surgical corrections. Postnatally, counseling and reassuring the parents and careful examination of umbilical defect should be done, and pediatric surgical referral should be considered to reach the proper diagnosis and reducibility of the contents. Choosing the proper line of management depends upon the umbilicus base as well as hernia contents, either by simple content reduction and sac ligation if the base is narrow and there is a short protrusion or by initial reduction, clamping, and immediate or later repair with cosmetic umbilicoplasty if the base is broad or there is a long-epithelialized protrusion around the umbilicus then surgical intervention is needed, but more mandatory if contents are not reducible or if there is bleeding or associated abnormalities that require surgical intervention. Once classical HUC was diagnosed, contents can be easily reduced by holding the sac upwards and doing gentle bowel milking into the peritoneal cavity. The fascia closed primarily, and cosmetic umbilicoplasty is always feasible which might be immediate or late. Care should be taken as the sac content is the midgut with or without the appendix, patent omphalomesenteric duct, or adhesions between the

bowel and sac [14] as what is found in the present study cases.

In our experience and that of others, HUC can be accompanied with additional anomalies such as congenital short gut, PVID, and intestinal, ileal, and colonic atresia as a result of intrauterine vascular accidents such as intussusception and volvulus [3]. In seldom cases, fetal demise is reported due to the rupture of the umbilical cord that led to in utero bowel evisceration and umbilical vessel rupture [16]. In this respect, Klein et al. reported the umbilical cord hernias associated with malrotation of the intestine [24]. Pal et al. described them as linked with cloacal anomalies, persistent vitello-intestinal duct, and atresia of the intestine [11]. Haas et al. [25] in their case series of eight patients recommended that HUC is associated with bowel complications such as cysts of the umbilical cord, dilation of the intestine, short bowel, and ascites. The authors advocated for close monitoring and early induction of labor between 34 and 36 weeks of gestation. Gupta et al. described a case of congenital HUC coupled with type 3 ileal atresia [26]. Pal et al. described an HUC case with gut perforation and extracelomic colonic atresia [27]. Mirza et al. reported a case series of three HUC cases: one case associated with in utero evisceration of whole small bowel through presumably ruptured HUC and other 2 cases associated with patent vitelointestinal duct [28]. In Patole1 et al. [29], most cases had ileal loops (49.42%) as the content of hernial sacs, 36.78% cases had Meckel's diverticulum, and 6.39% had cecum with the appendix. Mortality was reduced to 3.33% with fast detection of the disease, early management, and good postnatal care.

## Conclusions

HUC is an uncommon abdominal wall defect that may be underestimated due to limited awareness. Obstetricians and pediatric surgeons must be able to distinguish it from other umbilical and abdominal wall problems. Prenatal ultrasound screening for HUC and cord palpation before clamping the cord after birth are critical to minimize misdiagnosis and inadvertent intestinal harm. For proper diagnosis and management, health providers need more attention to possibility of HUC. On suspicion, proximal clamping of the cord should be avoided, with an immediate referral to a pediatric surgeon for the management of HUC according to its variable presentations. Forceful reduction should be avoided to avoid damaging the bowel while reducing the contents, keeping in mind the possible causes of irreducibility. This study stresses obstetricians' awareness of umbilical cord hernia, early detection, and pediatric surgeons' intervention to help newborns with a curable condition.

**Abbreviations**

AFP: Alpha-fetoprotein; HUC: Hernia of the umbilical cord; PVID: Patent vitellointestinal duct; USG: Ultrasonography.

**Acknowledgements**

Not applicable

**Authors' contributions**

All authors contributed equally in the writing and revising of the manuscript. Y.J. designed the study, contributed specifically to the patient selection and operative technique, and helped in writing the manuscript. M.K. contributed to the design of the manuscript, selection of the cases, and collection of the data and helped in the operative technique and in writing the manuscript. E.A.A. contributed to reviewing the obstetrical records and writing the related part of the manuscript. A.J. collected the data and helped in the literature review. S.A. contributed to reviewing the obstetrical records and writing the related part of the manuscript. All authors have read and approved the final manuscript for publication.

**Funding**

None.

**Availability of data and materials**

The datasets used and/or analyzed during the current study are available from the corresponding author on reasonable request.

**Declarations****Ethics approval and consent to participate**

Obtained from the Unit of Biomedical Ethics Research Committee (HA-02-J-008).

**Consent for publication**

Agree to consent for publication.

**Competing interests**

The authors declare that they have no competing interests.

**Author details**

<sup>1</sup>Department Of Pediatric Surgery, Faculty of Medicine, King Abdulaziz University, P.O. Box 80215, Jeddah 21589, Saudi Arabia. <sup>2</sup>Department of Obstetrics and Gynecology, Faculty of Medicine, King Abdelaziz University, Jeddah, Saudi Arabia.

Received: 31 March 2022 Accepted: 7 June 2022

Published online: 08 August 2022

**References**

- Raicevic M, Filipovic I, Sindjic-Antunovic S. Hernia of the umbilical cord associated with a patent omphalomesenteric duct. *J Postgrad Med*. 2017;63(1):58.
- Ghabisha S, Ahmed F, Al-wageeh S, Al-shami E, Al-naggar K, Obaid G, et al. Newborn with hernia umbilical cord: a case report and review of literature. *Open Access Surg*. 2021;14:17.
- Kumar C, Ali MM, Kadian YS. Congenital hernia of umbilical cord with patent vitellointestinal duct along with evisceration of gut—a rare presentation and unusual management. *Ann Pediatr Surg*. 2022;18(1):1–3.
- Laezza N, Mafra J, Figueiredo AM, Branco M, Cunha C. Umbilical cord hernia with Meckel's diverticulum. *J Pediatr Surg Case Rep*. 2022;7(6): 102140.
- Lucas AGT, Jaafar S, Mendez MD. Pediatric Umbilical Hernia. [Updated 2022 May 1]. In: StatPearls. Treasure Island: StatPearls Publishing; 2022. Available from: <https://www.ncbi.nlm.nih.gov/books/NBK459294/>.
- Maria S, Pedro-José L, Marina P, Carolina A. Umbilical cord hernia associated with a patent urachus: a case report. *Asploro J Pediatr Child Health*. 2020;2020(1):13.
- Philipp EE. Book review: victor bonney: the gynaecological surgeon of the twentieth century. London: SAGE Publications Sage UK; 2001.
- Slater BJ, Pimpalwar A. Abdominal wall defects. *NeoReviews*. 2020;21(6):e383–91.
- Hempel-Jorgensen P. Familial congenital umbilical hernia. *Ugesk f Laeger*. 1929;91:273–4.
- Achiron R, Soriano D, Lipitz S, Mashiach S, Goldman B, Seidman D. Fetal midgut herniation into the umbilical cord: improved definition of ventral abdominal anomaly with the use of transvaginal sonography. *Ultrasound Obstetr Gynecol*. 1995;6(4):256–60.
- Pal K, Ashri H, Al WA. Congenital hernia of the cord. *Indian J Pediatr*. 2009;76(3):319–21.
- Burns C, Ogryzlo M. Congenital hernia into the umbilical cord; two cases, one associated with persistent cloaca. *Can Med Assoc J*. 1938;39(5):438.
- Stanley-Brown EG, Frank JE. Mercury poisoning from application to omphalocele. *JAMA*. 1971;216(13):2144–5.
- Sherer DM, Dar P. Prenatal ultrasonographic diagnosis of congenital umbilical hernia and associated patent omphalomesenteric duct. *Gynecol Obstet Invest*. 2001;51(1):66–8.
- Bohilțea RE, Dima V, Ducu I, Iordache AM, Mihai BM, Munteanu O, et al. Clinically relevant prenatal ultrasound diagnosis of umbilical cord pathology. *Diagnostics*. 2022;12(2):236.
- Pakdamani R, Woodward PJ, Kennedy A. Complex abdominal wall defects: appearances at prenatal imaging. *Radiographics*. 2015;35(2):636–49.
- Verla MA, Style CC, Olutoye OO, editors. Prenatal diagnosis and management of omphalocele. *Semin Pediatr Surg*. 2019;28(2):84–8.
- Mansfield SA, Jancelewicz T. Ventral abdominal wall defects. *Pediatr Rev*. 2019;40(12):627–35.
- Bielicki IN, Somme S, Frongia G, Holland-Cunz SG, Vuille-dit-Bille RN. Abdominal wall defects—current treatments. *Children*. 2021;8(2):170.
- Mirza BSM. Hernia of umbilical cord with congenital short gut. *J Neonatal Surg*. 2014;3:26.
- Mirza BAW. Distinct presentations of hernia of umbilical cord. *J Neonatal Surg*. 2016;5:53.
- Ks I. Hernia of umbilical cord associated with cleft lip and palate, and congenital glaucoma. *J Neonatal Surg*. 2015;4:49.
- Gopagondanahalli KCA, Nataraja R, Tan K, Chandran S, Saiprasad T. Congenital hernia of umbilical cord masquerading as umbilical cyst and omphalocele on antenatal scans. *Med J DY Patil Vidyapeeth*. 2020;13:285–7.
- Klein MD, Kosloske AM, Hertzler JH. Congenital defects of the abdominal wall: a review of the experience in New Mexico. *JAMA*. 1981;245(16):1643–6.
- Haas J, Achiron R, Barzilay E, Yinon Y, Bilik R, Gilboa Y. Umbilical cord hernias: prenatal diagnosis and natural history. *J Ultrasound Med*. 2011;30(12):1629–32.
- Gupta R, Mathur P, Gupta PK. Congenital hernia of the umbilical cord associated with type IIIa ileal atresia. *J Neonatal Surg*. 2016;5(4):64.
- Pal K. Congenital hernia of the umbilical cord associated with extracolic colonic atresia and perforation of gut in a newborn. *Afr J Paediatr Surg*. 2014;11(1):74.
- Mirza B, Mirza A, Hashim I, Saleem M. Hernia of umbilical cord: report of three unusual cases. *J Neonatal Surg*. 2015;4(2):16.
- Patole MM, Patole MM, Paul S. Hernia of the umbilical cord: a clinical spectrum. *Int J Contemp Pediatr*. 2020;7(1):132–5.

**Publisher's Note**

Springer Nature remains neutral with regard to jurisdictional claims in published maps and institutional affiliations.