

CASE REPORTS

Open Access



Is pneumoperitoneum specific of post-traumatic appendicitis? Case report and literature review

Y. Kerkeni^{*} , F. Thamri, A. Zouaoui, S. Houidi and R. Jouini

Abstract

Introduction: Acute appendicitis and blunt abdominal trauma may co-exist, imposing a dilemma of whether there is only coincidence or there is a cause to effect relationship. The etiopathogenesis of this rare association remains obscure. Pneumoperitoneum has rarely been described in patients with acute perforative appendicitis following abdominal trauma.

Case presentation: We report a rare case of acute perforated appendicitis after blunt abdominal trauma in an 8-year-old boy revealed by a pneumoperitoneum. We also reviewed the literature on this rare condition to assess the specificity of pneumoperitoneum in the diagnosis and to understand its etiopathogenesis.

Conclusion: Abdominal pain and fever several days after an abdominal trauma may be a sign of post-traumatic appendicitis in the pediatric population. Pneumoperitoneum is not specific of post-traumatic appendicitis but it can be a protective sign, since it will lead to immediate laparotomy in patients with an unrecognized surgical abdomen.

Keywords: Pneumoperitoneum, Abdominal blunt trauma, Abdominal pain, Acute appendicitis, Case report

Introduction

Acute appendicitis is one of the most common diagnoses in acute surgical abdominal conditions. However, isolated post-traumatic appendicitis is a rare entity and many cases remain unreported due to concurrence with other intra-abdominal injuries [1, 2]. We report a rare case of an 8-year-old boy with pneumoperitoneum secondary to post-traumatic perforated appendicitis we managed at our academic institute. The report is in accordance with the SCARE guidelines 2020 [3]. We reviewed the literature on this rare condition to assess the specificity of pneumoperitoneum in the diagnosis of isolated post-traumatic acute appendicitis and to understand its etiopathogenesis.

Case report

An otherwise healthy 8-year-old boy was brought to the emergency department of our institution 10 h following a bicycle accident. He reported that he had run into a car and had struck at the lower abdomen by the bicycle's handlebar grip. He complained of abdominal pain and localized tenderness elicited by deep palpation of the right iliac fossa. The boy had no other abdominal complaints in his history before the abdominal trauma. No laceration, swelling, erythema, or tenderness was noted. No signs of trauma such as ecchymosis were detected, and the general clinical examination was normal. Blood analysis yielded hemoglobin 12.7g/dl, white blood cells (WBC) 7000/mm³, and C-reactive protein (CRP) 1 mg/l. Abdominal ultrasonography showed a small amount of abdominal free fluid with no sign of solid organ injury, whereas abnormal findings from the abdominal wall were not observed. Since the ultrasound was without abnormality, it was not considered essential to supplement the exploration with other radiological

*Correspondence: yosrakerkeni@yahoo.fr
Department of Pediatric Surgery "A", Children's Hospital, Tunis El Manar University, Tunis, Tunisia

examinations, and the patient was discharged home. Upon no improvement with conservative measures, the patient re-attended the emergency department 3 days later. He complained of diffuse abdominal pain with maximum in the right lower quadrant associated to anorexia, nausea, vomiting, and fever. His vital signs at admission were as follows: blood pressure 90/60 mmHg, heart rate 98/min, and respiratory rhythm 18/min. Axillary temperature was 38.7°C. Physical examination revealed generalized abdominal guarding with maximal tenderness in the right lower quadrant. The biological assessment has been redone, showing hemoglobin 12.9g/dl, WBC 13,600/mm³, and CRP 398 mg/l.

An erect plain abdominal X-ray was taken revealing free air under both copulae of the diaphragm (Fig. 1). Urgent abdominal ultrasonography showed a moderate free fluid on the right and left paracolic gutter and the pouch of Douglas.

In view of the evidence of free intraperitoneal gas, the history of trauma, and its mechanism, the top working diagnosis was a duodenal perforation.

A median laparotomy was performed. The stomach, duodenum, and the rest of the bowel were found to be healthy. The air leak test for perforated peptic ulcer was negative. The only pathology identified was a gangrenous

appendix disinserted at its basis (Fig. 2) leading to generalized peritonitis. There was no appendicolith, which is in favor of a traumatic disinsertion.

Appendectomy and abundant peritoneal lavage were done. Acute appendicitis with full-thickness inflammation of the appendix wall with a strong peritoneal reaction was confirmed by histopathology. The postoperative course was uneventful and the boy was discharged on postoperative day 7.

Discussion

Our patient was initially diagnosed having duodenal perforation considering the presence of pneumoperitoneum after flipping the handlebar of the bike. The diagnosis of post-traumatic appendicitis was missed.

Acute appendicitis caused by blunt abdominal trauma is very rare and has been reported sporadically in the literature [1, 2]. It was more described in children [2] as the transmission of kinetic energy is more pronounced due to a smaller abdominal cavity compared with adults.

In our case, the coexistence of acute appendicitis and blunt abdominal trauma as an incidental event is very unlikely. The patient had been asymptomatic before the trauma and biological and radiological assessments were normal at the first consultation.

The rate of co-occurrence of the perforation of acute appendicitis and pneumoperitoneum is about 0 to 7% [2]. The rate of pneumoperitoneum following traumatic

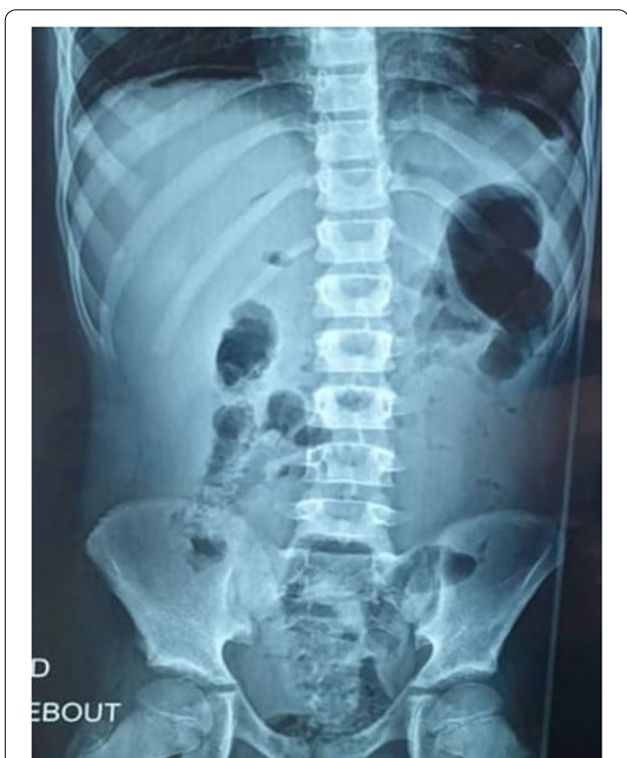

Fig. 1 Plain abdominal X-ray revealing free air under both copulae of the diaphragm

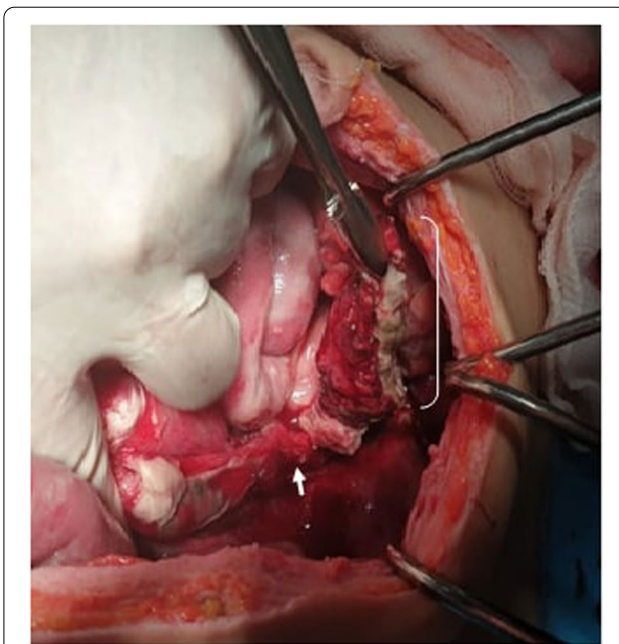


Fig. 2 Per-operative findings. White arrow: appendicular basis. White arch: gangrenous appendix disinserted at its basis

acute appendicitis has not been determined. Literature review showed that among 34 patients having post-traumatic appendicitis, almost 11% had pneumoperitoneum (Table 1) [1, 4–24].

Luminal air leak from perforated appendix resulting in pneumoperitoneum occurs when the appendiceal lumen is patent, a finding which could be more frequent in case of post-traumatic deinsertion of an initially healthy appendix. Blunt trauma might have a direct effect on the appendix with subsequent appendiceal injuries or detachment [25].

The theory which states that pneumoperitoneum might follow leakage of gas from a localized

periappendiceal abscess or bacterial gas production in gangrenous appendicitis [7, 8] seems also plausible since cases of post-traumatic appendicitis with pneumoperitoneum was reported in two patients having nonperforated appendicitis on surgical exploration [1, 4].

An indirect mechanism with increased intra-luminal pressure or irritation caused by muscle contraction can also participate to the formation of acute appendicitis. Power contractions of the iliopsoas might irritate the appendix causing adhesions, bands, angulations, or obstructions resulting in appendicitis [26].

The review of all cases of post-traumatic appendicitis had shown that the presence of pneumoperitoneum

Table 1 Literature review about the presence of pneumoperitoneum following post-traumatic acute appendicitis

Studies		Age (years)	Radiological assessments	Pneumoperitoneum	Appendicitis
Etensel et al. [4]	Patient 1	5	Ultrasonography + computed tomography	Yes	Not perforated
	Patient 2	8	Ultrasonography	No	Not perforated
	Patient 3	14	Ultrasonography	No	Not perforated
	Patient 4	9	Ultrasonography	No	Not perforated
	Patient 5	13	Computed tomography	No	Not perforated
Toumi et al. [1]		11	Abdominal X-ray	Yes	Not perforated
Ciftci et al. [5]	Patient 1	8	Not performed	NM	Perforated
	Patient 2	5	Not performed	NM	Not perforated
	Patient 3	13	Not performed	NM	Not perforated
	Patient 4	7	Ultrasonography	No	Perforated
	Patient 5	14	Ultrasonography	No	Not perforated
Serour et al. [6]	Patient 1	11	Not performed	NM	Not perforated
	Patient 2	8	Computed tomography	No	Not perforated
	Patient 3	7	Computed tomography	No	Perforated
Ramsook [7]		12	Computed tomography	No	Not perforated
Gupta et al. [8]	Patient 1	9	Abdominal X-ray	No	Perforated
	Patient 2	11	Computed tomography	No	Perforated
Amir et al. [9]		10	Ultrasonography + computed tomography	No	Not perforated
Volchoh et al. [10]		60	Computed tomography	No	Not perforated
Atallah et al. [11]		53	Computed tomography	No	Not perforated
Hegger et al. [12]		62	Computed tomography	No	Not perforated
Derr et al. [13]		41	Ultrasonography	No	Not perforated
Hennington et al. [14]	Patient 1	12	Not performed	NM	Not perforated
	Patient 2	46	Not performed	NM	Not perforated
Karavokyros et al. [15]		21	Ultrasonography	No	Not perforated
Musemeche et al. [16]		5	Computed tomography	No	Perforated
Osterhoudt et al. [17]		9	Computed tomography	No	Not perforated
Ramesh et al. [18]		11	Ultrasonography	No	Perforated
Stephenson et al. [19]		32	Not performed	NM	Not perforated
Takagi et al. [20]		45	Not performed	No	Not perforated
Zvizdic et al. [21]		7	Abdominal X-ray	Yes	Perforated
Paschos et al. [22]		17	Ultrasonography	No	Not perforated
Klis et al. [23]		12	Not performed	NM	Perforated
Moselmi et al. [24]		13	Abdominal X-ray	Yes	Perforated

NM not mentioned

was not a pathognomonic sign of this rare entity. The causal relationship between trauma and acute appendicitis remains unclear and the several theories suggested to explain their association remains debatable.

Post-traumatic appendicitis should be considered as a differential diagnosis of hollow organ perforations in children having blunt abdominal trauma. This aims to early recognition and treatment.

Our patient fulfills all the diagnostic criteria for traumatic appendicitis [7]: There was no history of abdominal pain before trauma and the trauma was caused by a direct and violent blunt force to the abdomen of limited duration with progressive worsening of signs and symptoms.

Conclusion

Trauma is not a well-known cause of appendicitis, and this can cause a delay in early management. An interval varying from a few hours to a few days until emergence of symptoms following trauma is a very suggestive feature of post-traumatic appendicitis. Even though pneumoperitoneum is not a pathognomonic sign of post-traumatic appendicular perforation, this radiographic finding is considered to be a protective sign, since it will lead to immediate surgical exploration either by laparotomy or laparoscopy in patients with an unrecognized surgical abdomen.

Acknowledgements

Not applicable.

Authors' contributions

KY drafted the manuscript. JR supervised the study. TF, ZA, and HS performed perioperative management of the patient. The authors read and approved the final manuscript.

Funding

No funding.

Availability of data and materials

Not applicable.

Declarations

Ethics approval and consent to participate

Not applicable.

Consent for publication

Written informed consent was obtained from the patient's parents for publication of this case report and accompanying images. A copy of the written consent is available for review by the Editor-in-Chief of this journal on request.

Competing interests

The authors declare that they have no competing interests.

Received: 25 October 2021 Accepted: 11 February 2022
Published online: 09 May 2022

References

- Toumi Z, Shan A, Hadfield MB, et al. Systematic review of blunt abdominal trauma as a cause of acute appendicitis. *Ann R Coll Surg Engl*. 2010;92:477–82.
- Kumar A, Muir MT, Cohn SM. The etiology of pneumoperitoneum in the 21st century. *J Trauma Acute Care Surg*. 2012;73:542–8.
- Agha RA, Franchi T, Sohrabi C, et al. The SCARE 2020 guideline: updating consensus surgical CAse REport (SCARE) guidelines. *Int J Surg*. 2020;84:226–30. <https://doi.org/10.1016/j.ijsu.2020.10.034>.
- Etensel B, Yazici M, Gursoy H, et al. The effect of blunt abdominal trauma on appendix vermiformis. *Emerg Med J*. 2005;22:874–7.
- Ciftci AO, Tanyel FC, Büyükpamukçu N, et al. Appendicitis after blunt abdominal trauma: cause or coincidence? *Eur J Pediatr Surg*. 1996;6:350–3.
- Serour F, Efrati Y, Klin B, et al. Acute appendicitis following abdominal trauma. *Arch Surg*. 1996;131:785–6.
- Ramsook C. Traumatic appendicitis: fact or fiction? *Pediatr Emerg Care*. 2001;17:264–6.
- Gupta R, Mathur V, Bansal J, et al. Acute appendicitis following blunt abdominal trauma in children: by chance or a cause? *Formos J Surg*. 2016;49:217–22.
- Amir A, Amir L, Waisman Y, et al. Acute appendicitis after a blunt perineal trauma: an illustrative case. *Pediatr Emerg Care*. 2009;25:184–5.
- Volchok J, Cohn M. Rare complications following colonoscopy: case reports of splenic rupture and appendicitis. *J Soc Laparosc Surg*. 2006;10:114–6.
- Atalla MA, Carangan M, Rozen WM. Acute traumatic appendicitis following blunt abdominal trauma. *ANZ J Surg*. 2010;10:1445–2197.
- Hagger R, Constantinou J, Shrotria S. Acute appendicitis after a fall from a ladder: a traumatic aetiology? *Emerg Med J*. 2002;19:366–7.
- Derr C, Goldner DE. Posttraumatic appendicitis: further extending the extended focused assessment with sonography in trauma examination. *Am J Emerg Med*. 2009;27(632):e5–7.
- Hennington MH, Tinsley EA Jr, Proctor HJ, et al. Acute appendicitis following blunt abdominal trauma. Incidence or coincidence? *Ann Surg*. 1991;214:61–3.
- Karavokyros I, Pikoulis E, Karamanakos P. A case of blunt abdominal trauma and posttraumatic acute appendicitis. *Ulus Travma Acil Cerrahi Derg*. 2004;10:60–2.
- Musemeche CA, Baker JL. Acute appendicitis: a cause of recurrent abdominal pain in pediatric trauma. *Pediatr Emerg Care*. 1995;11:30–1.
- Osterhoudt KC. Hocus-pocus: a case of abdominal pain after blunt abdominal trauma. *Pediatr Ann*. 2000;29:93–6.
- Ramesh G, Ho PW, Ng KL, et al. Appendicitis following blunt abdominal trauma. *Med J Malaysia*. 2002;57:123–4.
- Stephenson BM, Shandall AA. Seat-belt compression appendicitis. *Br J Surg*. 1995;82:325.
- Takagi Y, Yasuda K, Abe T. Seat belt compression appendicitis. *J Clin Gastroenterol*. 2000;31:184.
- Zvizdic Z, Pasic-Sefic I, Vranic S. Acute perforated appendicitis after blunt abdominal trauma: A report from a 7-year-old. *Am J Emerg Med*. 2020; 38(2): 408.
- Paschos KA, Boulas K, et al. Traumatic appendicitis in minor blunt abdominal injury. *EMA*. 2012;24:343–6.
- Klis S, Trang TL, Lutke MF. Posttraumatic appendicitis. *Ned Tijdschr Geneesk*. 2017;161:D458.
- Moselmi S, Foroortan HR, Tahamtan M. Co-incidence of acute appendicitis and appendiceal transection after blunt abdominal trauma: a case report. *Iran J Med Sci*. 2013;38(4):343–6.
- Xu X, Zheng C, Li B, He X. Gastrointestinal: pneumoperitoneum caused by acute perforated appendicitis. *J Gastroenterol Hepatol*. 2017;32(1):8.
- Galifer RB, Forgues D, Mourregot A, et al. Blunt traumatic injuries of the gastrointestinal and biliary tract in childhood. Analysis of 16 Cases. *Eur J Pediatr Surg*. 2001;11:230–4.

Publisher's Note

Springer Nature remains neutral with regard to jurisdictional claims in published maps and institutional affiliations.