

CASE REPORTS

Open Access



Another indication for a transanal pull-through: surgical management of rectal atresia—a case report

Rezkalla Akkary^{1*} , Nabil Diab² and Smart Zeidan²

Abstract

Background: Rectal atresia is a very rare cause of neonatal intestinal obstruction. It has some distinctive anatomical and physiological specifications. The management is controversial with many described operative techniques. In this case report, we described our patient that we operated according to the transanal pull-through technique. We discussed the advantages and disadvantages of this technique and what makes it a suitable option for this population of patient.

Case presentation: A full-term male patient presented at 36 h of life for a pneumoperitoneum. Because of his well-placed, normally appearing anus, the diagnosis of rectal atresia was delayed. The patient was operated then according to the transanal pull-through technique with good follow-up results.

Conclusion: Transanal pull-through is a safe, easy, and a potentially reproducible option for managing rectal atresia. It should be considered for managing future cases. More cases should be done before drawing big conclusions.

Keywords: Rectal atresia, Anorectal malformation, Transanal pull-through, Case report

Background

Rectal atresia (RA) is a very rare cause of neonatal intestinal obstruction; it comprises 1% of all cases of ano-rectal malformations (ARM) [1]. The anatomical significance of rectal atresia is the presence of normal anal canal and a well-developed anal sphincter [1, 2]. Many operative approaches are reported [3, 4]. According to Pena et al., a technique that preserves at least part of the anal canal is essential for a successful outcome in bowel control [1].

Our purpose was to report a case of rectal atresia that was successfully treated by transanal pull-through and colo-anal anastomosis after a complete preservation of the anal canal.

Case presentation

A 36-h-old, full-term, male baby, weighing 3.7 kg, with no antenatal history, was transferred to our center for a pneumoperitoneum. The child had not passed meconium yet. At the clinical exam, the child was irritable, with distended abdomen. Abdominal skin was erythematous. Perineal exam revealed normal external genitalia with a normally appearing anus. Urgent laparotomy showed a caecal perforation. The colon, sigmoid, and the rectum showed no gross anomaly. Full-thickness multiple biopsies were taken from throughout the colon in order to rule out Hirschsprung's disease. Using the perforation site, a caecostomy was performed. Pathological analysis confirmed the absence of Hirschsprung's disease. Distal colostogram with an intra-anal bougie had shown a cut-off sign at the level of the distal rectum, a few centimeters above the anus. No fistula was found. A silastic tube failed to pass through the anus. The diagnosis of rectal atresia was made. The cecectomy had an intractable pro-lapse and frequent watery output. Because of the water

*Correspondence: Akkari.rezkalla@ch-avignon.fr; r.akkary@gmail.com

² University of Balamand, Saint George University Hospital, Beirut, Lebanon

Full list of author information is available at the end of the article

and electrolyte loses and the difficulty handling the colostomy, 6 weeks after the laparotomy, the definitive surgical repair was done.

Surgical technique

The patient was installed in a lithotomy position with a urinary catheter draining the bladder. Our goal was to preserve the totality of the anal canal, so a transanal pull-through was done, in a fashion similar to that done in Hirschsprung’s disease, as shown in Fig. 1. Converting to a PSARP was planned in case of difficulty. After retracting externally the anus, using vicryl 4-0 sutures, we incised the posterior wall of the distal rectal pouch mucosa, 5 mm proximal to the dentate line. Using PDS 6-0 stay sutures, we continued the circular mucosal incision anteriorly. Submucosal dissection was started and we went for full-thickness dissection after 1 cm of submucosal dissection. Dissection was extended proximally reaching the end of the distal rectal pouch. After exteriorizing this pouch, a fibrous cord connecting the distal and proximal rectal pouches was reached, as shown in Fig. 2. The fibrous cord along with the proximal rectal pouch was adherent to the urinary bladder. Few centimeters of the proximal rectal pouch were liberated, as seen in Fig. 2, in order to eliminate the presence of multiple atresias. Colo-anal anastomosis was done, as shown in Fig. 3, preserving all the circumference of the anus. The duration of the procedure was 35 min.

Post-operative evolution

On the first postoperative day, the patient tolerated full oral feeds and was discharged home on the 3rd day. Six

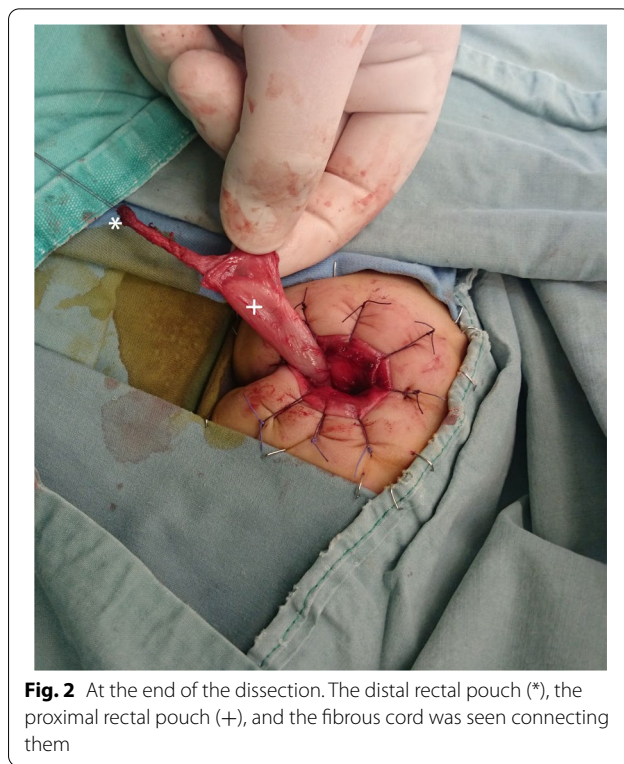


Fig. 2 At the end of the dissection. The distal rectal pouch (*), the proximal rectal pouch (+), and the fibrous cord was seen connecting them

weeks postoperatively, the caecostomy was closed and anal dilatation was done. Five years of follow-up were uneventful.

Discussion

RA is defined by the presence of a normally developed anus with no communication with the proximal colon [3, 5]. Unlike other types of ARM, the sphincter is well developed, and a good functional outcome is usually expected [5]. The anal canal might be about 1–3 cm in length [5]. In the Ladd and Gross classification, it was described as type 4 ARM [6]. RA is classified into 5 sub-groups [5], as illustrated in Fig. 4. Our patient had a type 3 RA according to Sharma and Gupta [5], which is the most common type [5]. Due to its rarity and the normal external appearance of the anus, the diagnosis is delayed [3, 7]. It manifests with failure to pass meconium, abdominal distention, and vomiting [1]. Although intestinal perforation in closed-loop intestinal obstruction is well known, its incidence in cases of ARM is variable, probably due to underreporting [8]. A diagnostic delay of more than 48 h is usually reported [8]; however, digestive tract perforations could happen earlier, as in our case. Sites of preoperative intestinal perforations vary, 68% in the recto-sigmoid; 18% in the cecum and proximal ascending colon, as in our case; 9% in the transverse colon; and 5% in other locations [8]. The classical approach for RA

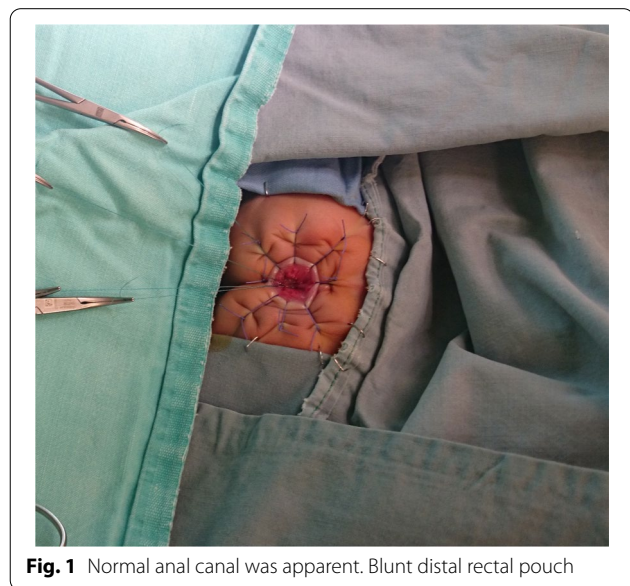


Fig. 1 Normal anal canal was apparent. Blunt distal rectal pouch

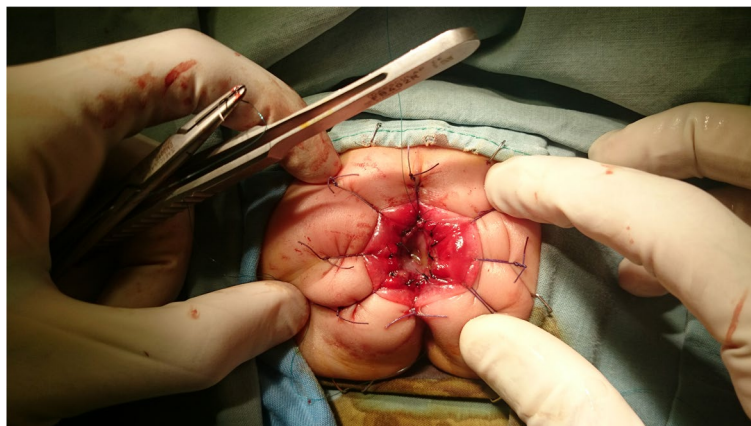


Fig. 3 Final result, transanal anorectoplasty

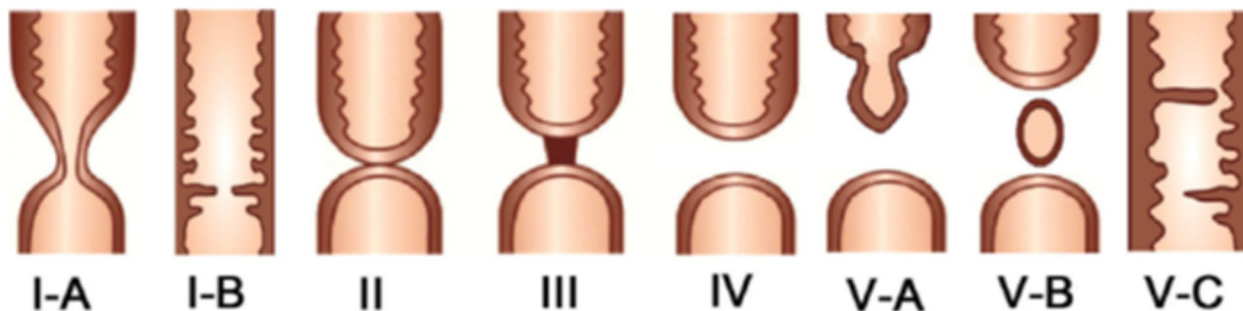


Fig. 4 Adopted from Sharma and Gupta [5]. Classification of rectal atresia. Type I: rectal stenosis: **A** intramural, **B** web; type II: rectal atresia with a septal defect; type III: rectal atresia with a fibrous cord between two atretic ends; type IV: rectal atresia with a gap; type V: multiple: **A** rectal atresia with stenosis, **B** multiple rectal atresia, and **C** thickened Houstons valves/multiple rectal stenosis

has been colostomy and delayed anastomosis [9]. Many different surgical procedures have been described [3, 7], ranging from simple perforation of the atresia, posterior sagittal anorectoplasty, and sacroabdominoperineal pull-through with widely different results [7]. These procedures involve dissection and division of pelvic floor muscles [2] and the resection of the anal canal [1, 9]. Hamrick et al. managed rectal atresia by modified posterior sagittal anorectoplasty, saving the anterior wall of the anal canal and dissecting the posterior wall only [3]. The advantage behind their approach is saving at least part of the anal canal and avoiding the complications of dissection within the anterior perineum and thus avoiding urethral, vaginal, vasal, and bladder injuries [1].

In our case, we chose to approach the RA by a transanal pull-through. The advantages of this technique are numerous. First of all, using this technique we were able to spare the totality of the anal canal [10]. Second of all, we did not need to dissect the pelvic floor muscles and a double approach was not needed since the

proximal rectal pouch was low in the pelvis. Finally, it was a scar-less approach. Despite all those advantages, the downsides of this approach are known from experiences derived from Hirschsprung’s disease: sphincter dilatation and adjacent hollow organs injuries. During the surgery in our case, only minimal anal sphincter retraction was practiced. The fibrous cord was avascular, and it had a small diameter. So a large working space in order to advance the dissection and the pull-through was not needed, contrary to the situation in Hirschsprung’s disease. Regarding the injury of other adjacent hollow organs, a meticulous step-by-step dissection by experienced hands was needed and was sufficient in order to avoid complications.

This entity is very rare and we had seen only one case. Although this technique is highly reproducible in the settings of Hirschsprung’s disease, we need to practice it more in the case of RA before confirming its reproducibility.

Conclusions

Transanal pull-through was possible with success in the management of our case of RA. It has many functional and esthetic advantages over other types of surgical procedures. We feel it is to be considered when managing RA. More cases are needed before confirming its reproducibility.

Abbreviations

RA: Rectal atresia; ARM: Anorectal malformations.

Acknowledgements

No acknowledgements to be stated

Authors' contributions

RA suggested the technique, operated the patient with SZ, and wrote the manuscript. RA with SZ did the literature review. SZ did the follow-up. ND supervised the work, validated the technique, and corrected and contributed to the manuscript. All three authors contributed to this work. All authors read and approved the final manuscript.

Funding

No funding to this work.

Availability of data and materials

Not applicable

Declarations

Ethics approval and consent to participate

Not applicable

Consent for publication

A written informed consent was obtained from the patient for publication of this case report and accompanying images

A written informed consent was obtained from a parent or guardian for participants under 18 years old.

Competing interests

The authors declare that they have no competing interests.

Author details

¹Pediatric Surgery Department, Avignon Public Hospital, 305 Rue Raoul Follereau, 84000 Avignon, France. ²University of Balamand, Saint George University Hospital, Beirut, Lebanon.

Received: 29 July 2021 Accepted: 22 October 2021

Published online: 01 February 2022

References

- Luo C-C, Ming Y-C, Chu S-M, Chao H-C. Individualized management of upper rectal atresia. *J Pediatr Surg*. 2009;44(112):2406–9.
- Liem NT, Hien PD. Laparoscopic and transanal approach for rectal atresia: a novel alternative. *J Pediatr Surg*. 2007;42(111):E25–7.
- Hamrick M, Eradi B, Bischoff A, Loudon E, Peña A, Levitt M. Rectal atresia and stenosis: unique anorectal malformations. *J Pediatr Surg*. 2012;47(16):1280–4.
- Boles ET Jr, Vassy LE, Ralston M. Atresia of the colon. *J Pediatr Surg*. 1976;11(11):69–75.
- Sharma S, Gupta DK. Varied facets of rectal atresia and rectal stenosis. *Pediatr Surg Int*. 2017;33:829–36.
- Gross RE, Ladd WE. *Abdominal surgery in infancy*. Philadelphia: WB Saunders; 1941. p. 166–87.
- Kisra M, Alkadi H, Zerhoni H, Ettayebi F, Benhammou M. Rectal atresia. *J Pediatr Child Health*. 2005;41(112):691–3.
- Raveenthiran V. Spontaneous perforation of the colon and rectum complicating anorectal malformations in neonates. *J Pediatr Surg*. 2012;47(14):720–6.
- Gieballa M, Alkharashi N, Al-Namshan M, AlJadaan S. Outcomes of transanal endorectal pull-through for rectal atresia. *BMJ Case reports*. 2012;18:1–6.
- Hamzaoui M, Ghribi A, Makni W, Sghairoun N, Gasmi M. Rectal and sigmoid atresia: transanal approach. *J Pediatr Surg*. 2012;47(16):E41–4.

Publisher's Note

Springer Nature remains neutral with regard to jurisdictional claims in published maps and institutional affiliations.

Submit your manuscript to a SpringerOpen® journal and benefit from:

- Convenient online submission
- Rigorous peer review
- Open access: articles freely available online
- High visibility within the field
- Retaining the copyright to your article

Submit your next manuscript at ► [springeropen.com](https://www.springeropen.com)