

ORIGINAL RESEARCH

Open Access



# Anorectal anomalies in the male: revisiting the radiological classification

Amr Abdelhamid AbouZeid<sup>1\*</sup> , Shaimaa Abdelsattar Mohammad<sup>2</sup>, Sherif Elhussiny Ibrahim<sup>3</sup> and Leila Rawash ElDieb<sup>2</sup>

## Abstract

**Background:** Classifying anorectal anomalies (ARA) has always been a matter of debate among pediatric surgeons. A new classification does not necessarily imply discarding older ones. Several concepts have been introduced in the past and stood the test of time being still valid up till now

In this report, we present our experience in managing a group of boys with ARA by PSARP. We have tried to enhance the current classification to include information about the level of the rectum in relation to sacrum, not just the location of the fistula.

**Results:** The study included 62 consecutive male patients with anorectal anomalies who underwent PSARP between 2009 and 2019. Included cases were either recto-bulbar fistula (21 cases), recto-prostatic fistula (30 cases), or imperforate anus without fistula (11 cases). Their age at operation ranged from 3 to 36 months (mean 7.8 months).

Cases with recto-prostatic fistula were further subclassified according to the level of distal rectum into two subgroups: (type 1) those with the rectum ending opposite the level of S4/S5, and (type 2) those with the rectum ending at a higher level opposite S3.

The PSARP procedure proved to be a successful surgical approach to reach, separate, and mobilize the rectum in all cases of recto-bulbar fistula, imperforate anus without fistula, and recto-prostatic fistula type (1). In cases of recto-prostatic fistula type (2), the perineal approach (PSARP) failed to reach and mobilize the rectum in two out of the eleven cases.

**Conclusion:** In management of anorectal anomalies, the sacrum can provide two important indicators: a prognostic value for continence, and anatomical landmark to stratify the level of distal rectum in the pelvis which is crucial for planning the best surgical approach.

**Keywords:** Recto-bulbar, Recto-prostatic, PSARP, Anorectal malformations, Colostogram, Imperforate anus

## Background

Classifying anorectal anomalies (ARA) has always been a matter of debate among pediatric surgeons [1]. Successive classification systems have been introduced that may indicate for a dynamic process of never-ending discussions without reaching to a final word on the issue

[1]. Each classification adds new concepts that help to increase our understanding about different aspects of the disease [1, 2]. A new classification does not necessarily imply discarding older ones that represented several years of studies and tedious work. Not only for history, but also for the several concepts that has been introduced in the past and stood the test of time being still valid up till now [1, 2].

Amussat is considered the first to start classifying ARA in 1835 [1, 2]. However, the major advance in the field has been attributed to the work of Stephens who

\* Correspondence: [amrabelhamid@hotmail.com](mailto:amrabelhamid@hotmail.com)

<sup>1</sup>Pediatric Surgery Department, Faculty of Medicine, Ain Shams University, Lotefy El-Sayed St., 9 Ain-Shams University Buildings, Abbassia, Cairo 11657, Egypt

Full list of author information is available at the end of the article

studied the anatomy of ARA on cadavers [3]. In 1963, Stephens and Smith used the radiological PC-line [4] to differentiate between two types of ARA, either low or high. Later at Wingspread, several clinical information have been added trying to represent the true diversity of the spectrum [1]. Influenced by the work of Alberto Pena, the pediatric surgical symposium at Krickenbeck finally reached a consensus, which classified ARA into major clinical groups and other rare/regional variants [5].

In this study, we present our experience in managing a group of boys with ARA by Posterior Sagittal AnoRectoPlasty (PSARP) [6] highlighting some anatomical considerations based on the analysis of their preoperative imaging. We tried to apply new stratification based on identifying the level of distal rectum in relation to corresponding sacral vertebrae.

## Methods

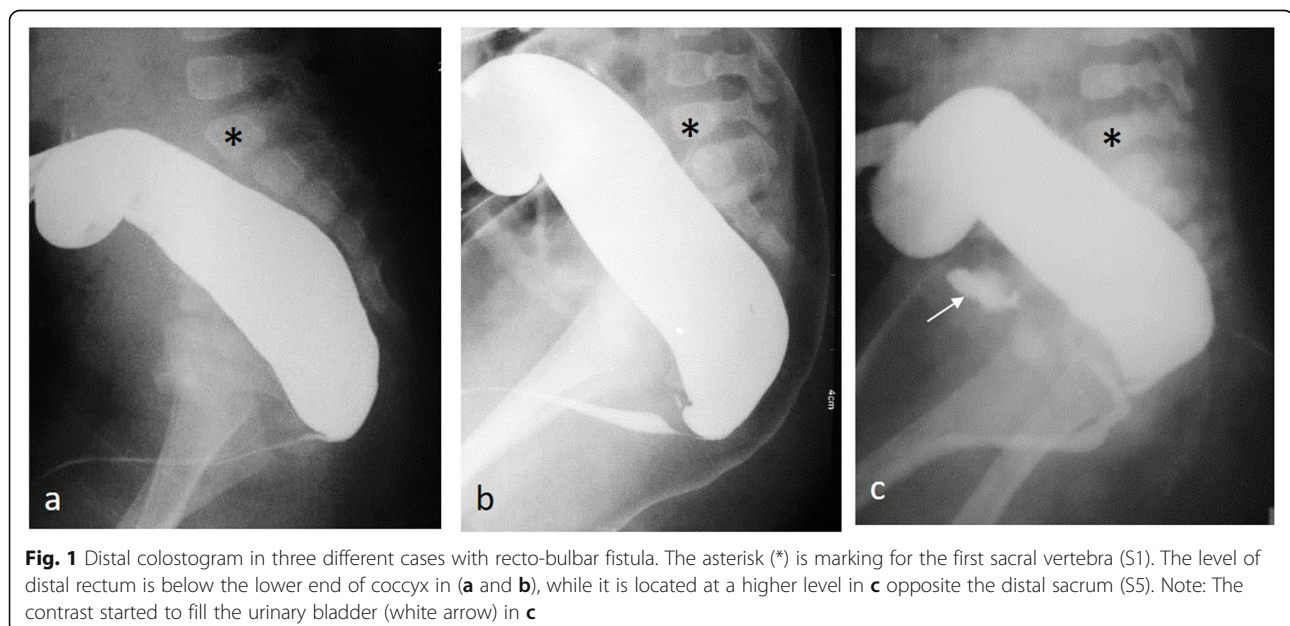
Database maintained by the author for male patients with anorectal anomalies (ARA) was retrospectively reviewed. The study included cases with recto-urethral fistulae (recto-bulbar/prostatic), as well as cases of imperforate anus without fistula who underwent PSARP [6] by a single surgeon (the author) during the period 2009 through 2019. At the extreme end of the spectrum, cases with recto-vesical fistulae were excluded from the study when the decision was made for an abdominal approach from the start. Also, we excluded cases with rectoperineal fistulae that has been discussed in previous reports [7], as well as cases associated with presacral masses (Currarino triad) [8]. All included cases underwent staged repair: colostomy at birth, followed by PSARP later in infancy, and finally closure of colostomy.

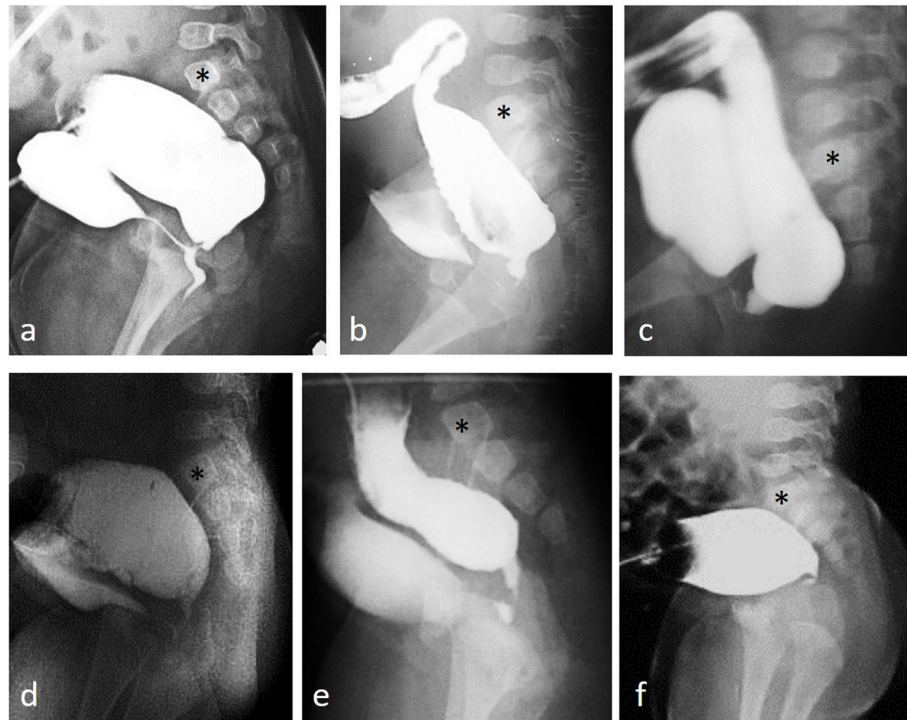
Owing to the retrospective nature of the study, an IRB number was not required, and the study was approved through expedited review by the scientific/ethical committee of the Pediatric Surgery Department.

## Preoperative investigations

Pelviabdominal ultrasound and echocardiography were performed to screen for possible associated renal and cardiac anomalies. Distal colostogram was the standard investigation to identify the location of distal rectum and level of fistulous communication with the urinary tract. Following the standard recommendations, water-soluble contrast was injected into the distal colostomy under constant gentle pressure to visualize any minute communication with the urinary tract [9]. According to the current 'Krickenbeck' classification for anorectal malformations [5], cases were divided into three clinical groups: recto-bulbar (Fig. 1), recto-prostatic (Fig. 2), and imperforate anus without fistula (Fig. 3). Based on retrospective analysis of operative findings in relation to preoperative imaging, cases with recto-prostatic fistula were further subclassified according to the level of distal rectum into two subgroups (Fig. 2): (type 1) those with the rectum ending opposite the level of S4/S5 that were associated with a relatively more easier dissection at operation (more or less similar to recto-bulbar), and (type 2) those with the rectum ending at a higher level opposite S3 when more careful dissection was needed to go above urogenital structures (prostate/seminal vesicles) that were frequently encountered in the surgical field.

In selected cases (significant sacral dysplasia), MRI was ordered to detect possible associated spinal anomalies. In a single case with stenosis at the skin site of distal





**Fig. 2** Distal colostogram in six different cases with recto-prostatic fistula. The asterisk (\*) is marking for the first sacral vertebra (S1). The upper row (a, b, c) recto-prostatic fistula type 1: the distal rectum terminates at the level of S5 in a and at the level of S4 in b and c. Note the degree of sacral dysplasia in c: absent last piece and fusion between 2nd and 3rd pieces. The lower row (d, e, f) recto-prostatic fistula type 2: the distal rectum terminates at a higher level (S3). Note the missing last sacral piece in d and e compared to the complete sacrum in f. In cases with recto-prostatic fistula, it is common to find the distal rectum terminating at a higher level while communicating with the urethra at a lower level via a narrow fistulous tract (b, d, and e)

colostomy (Fig. 4a), pelvic MRI was used to identify the position of the rectum as an alternative to failed conventional contrast studies (Fig. 4b).

#### **Operative technique (PSARP)**

For cases with rectourethral fistula, a standard PSARP procedure was performed in the prone position [10]. The steps of the procedure are summarized in Fig. 5. An exactly similar technique was applied for cases of imperforate anus without fistula as a common wall was always present between the rectum and urinary tract even in absence of direct fistulous communication (Fig. 3d, e).

In cases of recto-prostatic fistula, the rectum was usually located higher in position. This was more pronounced in recto-prostatic fistula ‘type 2’ (Fig. 6). When the rectum was too deep in the pelvis to be approached from below (perineal approach), we shifted to a combined abdomino-perineal approach. In such situation, rectal dissection and separation were completed through the abdomen, then the mobilized rectum was pulled down to the perineum through the posterior sagittal incision (Fig. 7).

#### **Outcome assessment of the ‘PSARP’ procedure**

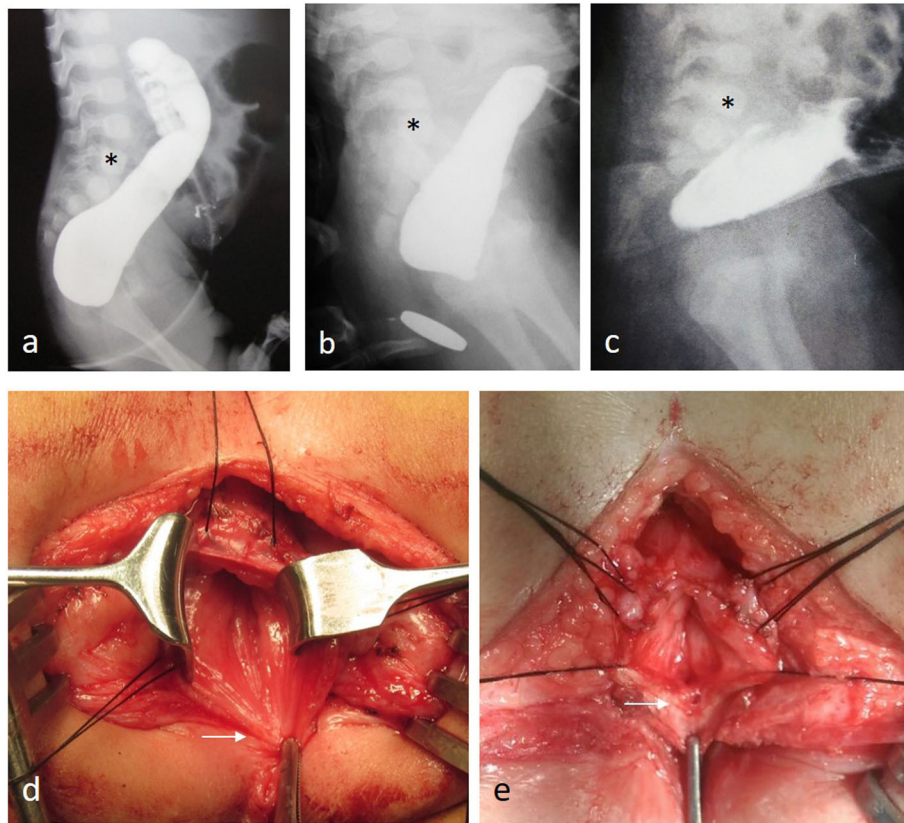
This included early postoperative complications as well as delayed surgical complications that required reoperations (anal stenosis, mucosal ectropion). Delayed functional outcome assessment was performed for operated cases who kept following at the outpatient clinic; while others were contacted by phone and asked about their stooling pattern. Assessment of functional outcome was performed according to the Krickenbeck classification for postoperative results: voluntary bowel control, soiling, and constipation [5].

#### **Results**

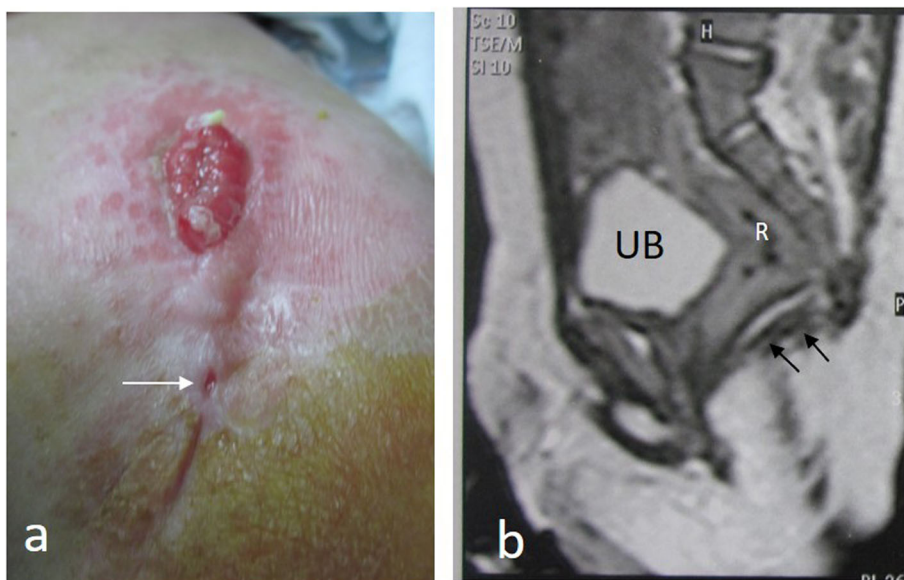
The study included 62 consecutive male patients with anorectal anomalies who underwent PSARP between 2009 through 2019. Included cases were either rectobulbar fistula (21 cases), recto-prostatic fistula (30 cases), or imperforate anus without fistula (11 cases). Their age at operation ranged from 3 to 36 months (median 6 months; mean 7.8 months).

Complementary to the current classification (rectobulbar, recto-prostatic, and imperforate anus without fistula) [5], we applied further stratification depending on

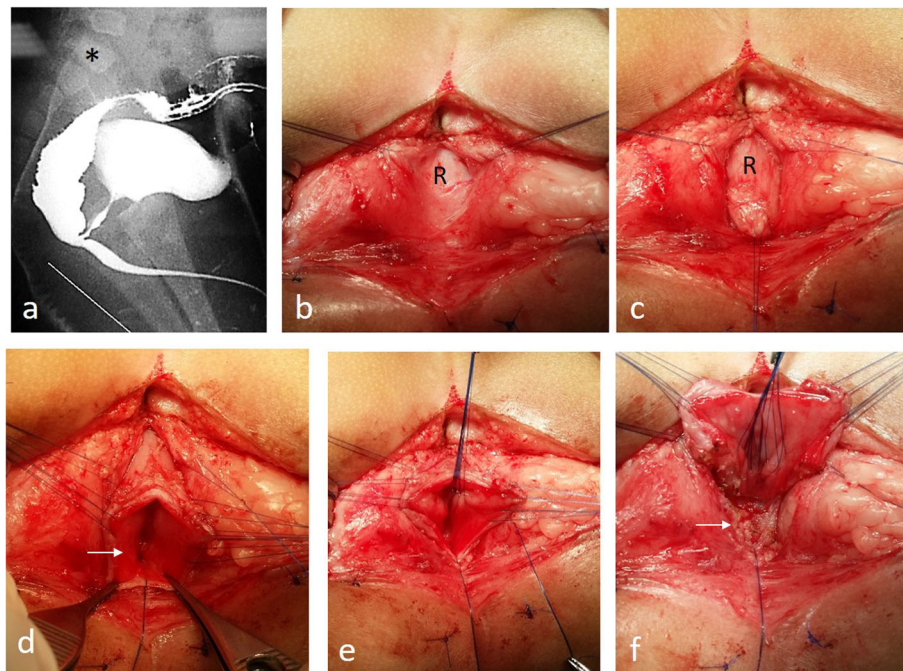




**Fig. 3** Imperforate anus without fistula. Upper row (**a, b, c**): distal colostogram of three different cases; asterisk (\*) is marking for the first sacral vertebra (S1). Note the different level of rectal termination: **a** below sacrum; **b** at the lower end of sacrum; **c** opposite S4. The lower row (operative pictures at PSARP) (**d, e**): a longitudinal incision is made through the posterior rectal wall demonstrating the convergence of the rectal mucosa toward a point tightly adherent to the urinary tract anteriorly (arrow) without direct fistulous communication



**Fig. 4 a** A case with recto-prostatic fistula presenting with stenosis at the skin site of distal colostomy (arrow). **b** Pelvic MRI was used to identify the level of the rectum (R) in relation to the sacrum and the levator muscle (black arrows). UB: urinary bladder



**Fig. 5** A 3-month-old boy with recto-bulbar fistula underwent PSARP. **a** Preoperative distal colostogram. **b, c** The diaphragmatic part of the levator ani is incised in the midline to expose the rectum (R). **d** A midline incision is made through the posterior rectal wall to expose the fistula from inside (white arrow). **e, f** Separation of the anterior rectal wall, leaving the fistula in place (white arrow) attached to the urinary tract to be closed by running sutures

identifying the level of distal rectum in relation to corresponding sacral vertebrae (Table 1) [11]. In cases with recto-bulbar fistula (Fig. 1), the distal rectum was located either at or below the level of fifth sacral vertebra (S5). On the other hand (Fig. 2), we could differentiate between two subgroups of recto-prostatic fistula with different degrees of severity from the surgical point of view: (type 1; 19 cases) those with the rectum ending opposite the level of S4/S5, and (type 2; 11 cases) those with the rectum ending at a higher level opposite S3. The level of distal rectum in cases of imperforate anus without fistula was similar to recto-bulbar group (at or below S5) except in one case that was located at the level of S4 (fourth sacral vertebra) (Fig. 3). Another anatomical consideration was the frequent absence of coccyx and last sacral vertebra in cases of recto-prostatic fistula (Fig. 2) that has been observed to ‘relatively’ facilitate the surgical access to the rectum from below.

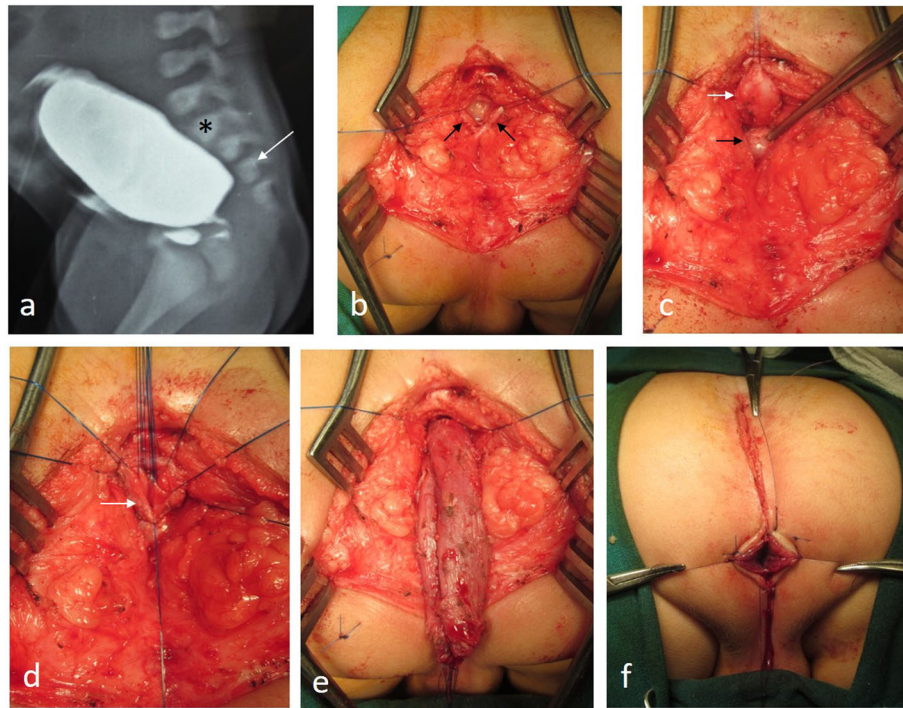
The PSARP procedure proved to be a successful surgical approach to reach, separate, and mobilize the rectum in all cases of recto-bulbar fistula, imperforate anus without fistula, and recto-prostatic fistula type (1). In cases of recto-prostatic fistula type (2), the perineal approach (PSARP) failed to reach and mobilize the rectum in two out of the eleven cases. Retrospective analysis has shown the level of distal rectum to be exceptionally high in one case (opposite S2; Fig. 7); while the other case

had an unusual complete sacrum and coccyx despite a high distal rectum opposite S3 (Fig. 2f).

Associated renal anomalies were relatively more common among recto-prostatic fistula (33%) compared to recto-bulbar (19%) and imperforate anus without fistula (9%). The distribution of associated renal anomalies among different study groups is summarized in (Table 2). A single kidney was found in nine and hydronephrosis in six cases. All cases with associated renal anomalies were advised to follow at the pediatric nephrology/urology clinic. Voiding cystourethrograms studies were available in three out of six cases with hydronephrosis that confirmed the presence of vesico-ureteric reflux. All cases were managed conservatively, and no one needed intervention. Associated cardiac anomalies were less common (4 cases) that ranged from simple anomalies (ASD, PDA) to more complex anomalies (Fallot tetralogy in one case). Out of the 11 cases of imperforate anus without fistula, 3 were associated with Down syndrome.

Sacral vertebral anomalies were a common finding (50%). The different degrees of sacral dysplasia and its distribution among different study groups are summarized in (Table 3). Again, the incidence of sacral dysplasia was more common among recto-prostatic fistula (66%) compared to other study groups (35%). By matching data in Tables 1 and 3, we found the level of distal rectum to correlate with the degree of sacral dysplasia;





**Fig. 6** A 4-month-old boy with recto-prostatic fistula underwent PSARP. **a** Preoperative distal colostogram showing high distal rectum opposite S3 (arrow). **b** The diaphragmatic part of the levator ani is incised in the midline (black arrows). **c** We had to go above the prostate (black arrow) to reach the rectum (white arrow). **d** A midline incision is made through the posterior rectal wall to expose the fistula from inside (white arrow). **e** After separation of the anterior rectal wall, we continue with perirectal dissection until the length of rectum is sufficient to reach down to the perineum. **f** The neo-anus is fixed in its normal predestined location within the striated muscle complex

the higher the rectum, the more the dysplasia (Spearman rank correlation test,  $p$  value < 0.0001). High termination of the spinal cord (T12) was detected in one case with severe sacral dysplasia (caudal regression).

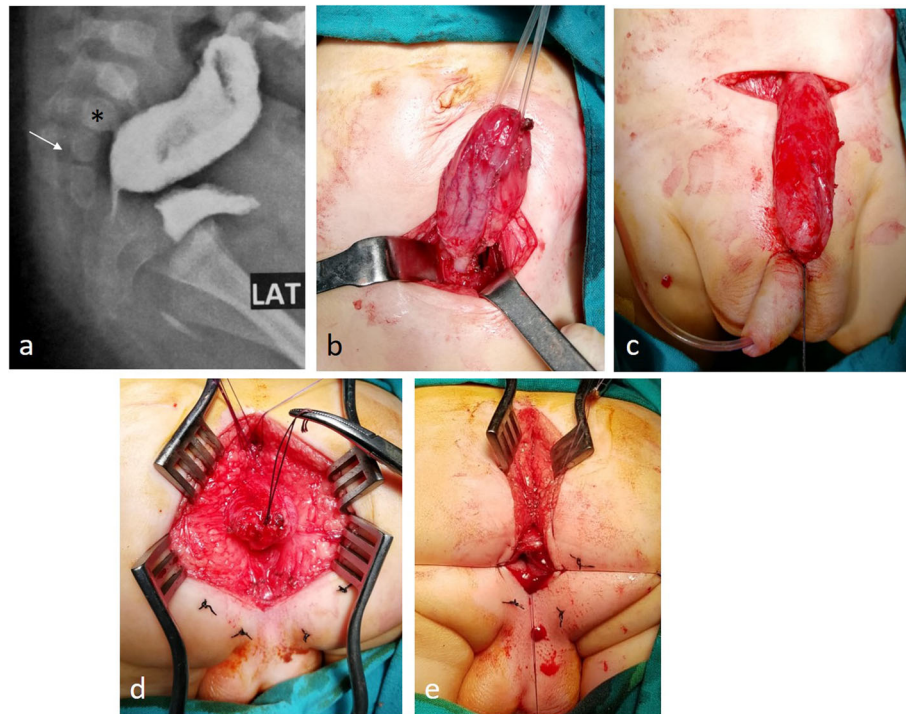
Regarding the operative outcome of the ‘PSARP’ procedure, partial wound disruption was noticed in two cases that were managed conservatively without delayed consequences. Delayed anal stenosis occurred in three cases; two of them required simple anoplasty, while a reoperation was needed in the third case that was associated with retraction of the neo-anus. Owing to the low incidence of postoperative complications, no significant difference was observed between different study groups. On the other hand, excess anal mucosa (mucosal ectropion) was the most common postoperative complication (10 cases) that required reoperation to remove everted mucosa in 8 (some of these were performed at time of colostomy closure).

At time of the study, 19 of the operated cases were still below 3 years of age (the age of start of bowel control) [5]. Out of the remaining 43 cases, 17 were available for assessment of postoperative functional outcome (Table 4). Their age ranged from 3 to 10 years at time of delayed functional assessment (median 7; mean 6.7). Voluntary bowel control was present in 14 cases (82%).

Three cases did not achieve voluntary bowel control: two of them had significant sacral dysplasia (3 pieces deficient); a third case was a 3-year-old boy with good sacrum but with delayed mental milestones (Down syndrome). Constipation was present in eight cases (47%). Faecal soiling was a common postoperative finding (88%); however, soiling was mild (occasional) in one third of affected cases. On the other hand, moderate and severe soiling were more commonly associated with constipation (8 cases) and in two cases with significant sacral dysplasia (no bowel control). Management of constipation (stimulant laxatives) was associated with improvement of faecal soiling.

## Discussion

Ano-rectal anomalies represent a diverse spectrum with different expression in the male and female [1]. A thorough understanding of both normal and pathological anatomy is a prerequisite for proper planning of reconstructive surgery [1]. Over successive years, a multitude of classification systems have been proposed based on embryological and radiological studies, as well as clinical and surgical observations [1]. In 2005, a new international classification system ‘Krickbeck’ was born trying to unify terminology so that pediatric surgeons all



**Fig. 7** A 6-month-old boy with recto-prostatic fistula underwent PSARP that failed to mobilize the rectum from below, so we shifted to abdominal approach. **a** Preoperative distal colostogram showing high distal rectum opposite S2 (arrow). **b** Dissection of distal rectum through abdominal incision. **c** Testing the length of the distal rectum whether it can reach down to the perineum. **d** The mobilized rectum is pulled down to the perineum through the posterior sagittal incision. **e** The neo-anus is fixed in its normal predestined location within the striated muscle complex

over the world would speak a common language [5]. The new classification was not only for the diagnosis, but also involved grouping of surgical procedures and postoperative results [5].

Since its introduction in 1982 [6], the PSARP procedure has gained widespread acceptance to become the standard technique for repair of ARA with rectourethral fistula in most pediatric surgical centers all over the world [10]. Through its perfect exposure, the trans-rectal approach to the fistula protects the urinary tract from possible iatrogenic injuries [10]. Protection of pelvic innervation is also feasible by sticking to the rectal wall during pelvic dissection. In this study, we present the surgical outcome of 62 consecutive cases belonging to two major clinical groups of ARA in the male (rectourethral fistula, and imperforate anus without fistula) [5] who were treated by the same surgical procedure (PSAR

P) and same surgeon. Digital archiving included pre-operative investigations and operative findings that were available for retrospective analysis.

Based on operative experience through this study group, the level of mid sacral vertebra (S3) was found to represent an important landmark indicating for the feasibility of perineal approach to mobilize the distal rectum. Below this level (when distal rectum was located opposite S4-S5), the PSARP procedure was a straightforward approach to reach and mobilize the rectum; this was feasible in 51 consecutive cases. Meanwhile, a distal rectum located opposite the level of S3 (recto-prostatic fistula type 2) represents a 'grey zone' that can be approached from above (abdominal approach) or from below (perineal approach). Although the perineal approach (PSARP) was successful in 90% in this particular subgroup (nine out of ten consecutive cases), yet a

**Table 1** Position of the distal rectum in relation to corresponding sacral vertebrae among different study groups

	Position of the distal rectum in relation to corresponding sacral vertebrae				
	Below S5	At level of S5	At level of S4	At level of S3	At level of S2
Recto-bulbar fistula (21 cases)	16	5	–	–	–
Recto-prostatic fistula (30 cases)	–	3	16	10	1
Imperforate anus without fistula (11 cases)	4	6	1	–	–

**Table 2** Distribution of associated renal anomalies among different types of anorectal anomalies in the male

	Single kidney	Hydroureteronephrosis	Total
Recto-bulbar fistula (21 cases)	3	1	4 (19%)
Recto-prostatic fistula (30 cases)	6	4	10 (33.3%)
Imperforate anus without fistula (11 cases)	–	1	1 (9%)

higher level of surgical experience was needed to go with the dissection safely above urogenital structures that were frequently encountered in the surgical field. Here, the absent coccyx and last sacral piece may turn to be a favorable association that facilitates the access to the rectum from below when it becomes ‘relatively’ more superficial. Consequently, it is quite expected that a distal rectum located above S3 will be more accessible from above through abdominal/laparoscopic approach similar to recto-vesical fistula (only one case in this series with distal rectum opposite S2).

In this report, we emphasize on the well-known value of the distal colostogram in preoperative assessment for cases of anorectal anomalies. Not only for detection of presence and site of the fistula, but also other anatomical considerations should be looked for. The level of distal rectum in relation to the corresponding sacral vertebrae and the developmental status of the sacrum can alter the decision on how to approach the rectum. These anatomical considerations should be well studied and matched with the experience of the surgeon before attempting to dig the perineum in a blind manner from below searching for the rectum. This is especially important when dealing with cases lying in the grey zone (recto-prostatic fistula type 2). Although the perineal approach may be preferable (rapid recovery and avoids going through the abdomen), yet under certain circumstances (specific anatomy and surgeon’s experience), it might be safer to plan for an abdominal/laparoscopic approach from the start.

Fecal continence represents the primary functional outcome. Among several factors that affect continence, the degree of sacral dysplasia is of utmost importance [12]. Again, the middle sacral vertebra (S3) proved to

play an important prognostic role in this respect; most authors would agree that the deficiency of more than two sacral pieces would be associated with poor prognosis for continence [12]. Pena innovated a sacral ratio that would be calculated on plain X-ray to judge on the degree of sacral dysplasia in a more objective way [12]. In this report, 17 cases were available for postoperative functional assessment using the Krickbeck classification for postoperative results. Significant sacral dysplasia (three pieces deficient) was associated with lack of voluntary bowel control and severe soiling in two cases (recto-prostatic). The third case lacking voluntary bowel control had a good sacrum but delayed mental milestones (Down syndrome). Otherwise, all cases had voluntary bowel control (82%). On the other hand, the incidence of constipation was 47%, while significant fecal soiling (excluding mild occasional soiling) occurred in 59%. Except in the two cases with significant sacral dysplasia, soiling showed improvement with treatment of constipation. Although recto-prostatic fistula was associated with higher incidence and more severe degrees of sacral dysplasia, yet the number of cases available at follow-up in each group was too small to make sound comparison regarding the functional outcome.

Lastly, we came to a group of observations that we believe might be beneficial during surgical planning for these cases:

- Although classifying recto-urethral fistula into two subgroups (either recto-bulbar or recto-prostatic) is indicative for two different degrees of severity; however, this does not truly reflect all variants that can be seen in the spectrum. Moreover, there are no sharp boundaries existing between the two

**Table 3** Distribution of sacral abnormalities among different types of anorectal anomalies in the male

	Degree of sacral dysplasia				Total
	Complete sacrum but fused vertebrae (segmentation anomalies)	Missing one sacral vertebra	Missing two sacral vertebrae	Missing three sacral vertebrae	
Recto-bulbar fistula (21 cases)	4	2	–	1	7 (33.3%)
Recto-prostatic fistula (30 cases)	10	6	2	2	20 (66.6%)
Imperforate anus without fistula (11 cases)	3	1	–	–	4 (36.4%)



**Table 4** Assessment of functional outcome in male patients after PSARP operation using Krickenbeck classification for postoperative results

	Cases available for functional assessment	Voluntary bowel movements	Constipation			Fecal soiling		
			Mild (diet management)	Moderate (managed by laxatives, mostly senna derivatives)	Severe (resistant to diet and laxatives)	Mild	Moderate	Severe
Recto-bulbar fistula	6	6 (100%)		3		3	2	1
Recto-prostatic fistula	9	7 (77.7%)		3	1	2	4	2
Imperforate anus without fistula	2	1 (50%)			1			1
Total	17	14/17 (82%)	8/17 (47%)			15/17 (88%)		

subgroups. A transitional overlap can often be observed (once has been described as recto-membranous).

- The level of distal rectum in the pelvis is usually but not always consistent with the site of the fistula [11]. The distal rectum may be located at a higher level while still communicating with the urethra at a lower level via a narrow fistulous tract (this is a relatively more common finding with recto-prostatic fistula).
- Practically speaking, the identification of the site of fistula needs to be complemented by identifying the level of distal rectum. Current surgical practice entails starting the dissection by the distal rectum to be followed by trans-rectal separation of the fistula. In this study, we could differentiate between two different degrees of severity among operated cases with recto-prostatic fistula depending on the level of distal rectum.
- The way of rectal termination (whether with or without fistula) does not appear to have a major impact on surgical decision. A common wall between rectal termination and the urinary tract anteriorly is almost always a constant finding in all cases even in absence of direct fistulous communication. Therefore, the same technique is applied for separation of the anterior rectal wall from the urinary tract in both groups.

Based on the above observations, we may need to revisit the anatomical classification of Stephens and Smith (1963) who used bony landmarks (the famous PC-line) to differentiate radiologically between a low and a high rectum. Using similar concept, we highlight a possible role for the sacrum in stratifying ARA [11]. Besides its well-known impact on the prognosis for continence, the sacral vertebrae can provide a scale for grading the level of distal rectum. Despite the obvious advantages of current classification of ARA into clinical groups [5], it

appears that we are still in need for complementary anatomical stratification. Almost all clinical types share a common anatomical (embryological) feature which is the intimate relation (common wall) with the urogenital tract anteriorly. It remains always safer to start surgical dissection at the distal rectum posteriorly, and hence, the level of the distal rectum will remain the most decisive factor on surgical approach.

The limitation of the study may be related to its retrospective nature and the relatively small number of cases. However, the detailed digital archiving of preoperative investigations and operative findings greatly mitigated these drawbacks. Moreover, among the diversity of different types and procedures for ARA, included cases represented a relatively homogenous group who underwent the same procedure (same surgeon).

**Conclusion**

In management of anorectal anomalies, the sacrum can provide two important indicators: a prognostic value for continence, and anatomical landmark to stratify the depth of distal rectum in the pelvis which is crucial for planning the best surgical approach.

**Abbreviations**

ARA: Anorectal anomalies; PSARP: Posterior Sagittal AnoRecto-Plasty; MRI: Magnetic resonance imaging; ASD: Atrial septal defects; VSD: Ventricular Septal defects; IRB: Internal Review Board

**Acknowledgements**

None

**Authors' contributions**

Data acquisition was performed by all authors. AAA made the study design, analysis, and data interpretation, as well as drafting of the manuscript. SEI, SAM, and LRE performed critical revision. All authors have read and approved the final manuscript.

**Funding**

None

**Availability of data and materials**

The datasets used and/or analyzed during the current study are available from the corresponding author on reasonable request.

### Ethics approval and consent to participate

A written parental consent was taken before operation in all cases. Owing to the retrospective nature of the study, an IRB number was not required, and the study was approved through expedited review by the scientific/ethical committee of the Pediatric Surgery department (Faculty of Medicine, Ain-Shams University).

### Consent for publication

Patient identity did not appear in any part of the manuscript; therefore, consent for publication was not required.

### Competing interests

The authors declare that they have no competing interests.

### Author details

<sup>1</sup>Pediatric Surgery Department, Faculty of Medicine, Ain Shams University, Lotefy El-Sayed St., 9 Ain-Shams University Buildings, Abbassia, Cairo 11657, Egypt. <sup>2</sup>Department of Radiodiagnosis, Faculty of Medicine, Ain Shams University, Cairo, Egypt. <sup>3</sup>Benha Specialized Children Hospital, Banha, Egypt.

Received: 24 June 2020 Accepted: 20 October 2020

Published online: 15 December 2020

### References

1. Murphy F, Puri P, Hutson JM, Holschneider AM. Incidence and frequency of different types, and classification of anorectal malformations. In: Holschneider AM, Hutson JM, editors. *Anorectal malformations in children*. Berlin Heidelberg: Springer-Verlag; 2006. p. 163–82.
2. Pena A, Bischoff A: History of the Treatment of Anorectal Malformations. In: *Surgical treatment of colorectal problems in children*. Springer 2015; pp: 1-16.
3. Stephens FD. Congenital imperforated rectum, recto-urethral and recto-vaginal fistulae. *Aust N Z J Surg*. 1953;22:161–72.
4. Wangensteen OH, Rice CO. Imperforate anus. A method of determining the surgical approach. *Ann Surg*. 1930;92:77–81.
5. Holschneider A, Hutson J, Pena A, Bekhit E, Chatterjee S, Coran A, et al. Preliminary reports on the international conference for the development of standards for the treatment of anorectal malformations. *J Pediatr Surg*. 2005;40:1521–6.
6. DeVries PA, Pena A. Posterior sagittal anorectoplasty. *J Pediatr Surg*. 1982;17: 638–43.
7. AbouZeid AA, Mohammad SA. Low-type anorectal malformations in the male: extent of deviation from the norm. *J Pediatr Surg*. 2016;51:1851–8.
8. AbouZeid AA, Mohammad SA, Abolfotoh M, Radwan AB, Ismail MME, et al. The Currarino triad: what pediatric surgeons need to know. *J Pediatr Surg*. 2017;52:1260–8.
9. Bekhit E, Murphy F, Puri P, Hutson JM. The clinical features and diagnostic guidelines for identification of anorectal malformations. In: Holschneider AM, Hutson JM, editors. *Anorectal malformations in children*. Berlin Heidelberg: Springer-Verlag; 2006. p. 185–200.
10. Levitt MA, Pena A. Operative management of anomalies in males. In: Holschneider AM, Hutson JM, editors. *Anorectal malformations in children*. Berlin Heidelberg: Springer-Verlag; 2006. p. 295–302.
11. Bischoff A. The surgical treatment of cloaca. *Semin Pediatr Surg*. 2016;25: 102–7.
12. Pena A, Bischoff A: Imaging. In: *Surgical treatment of colorectal problems in children*. Springer 2015; pp: 77-99.

### Publisher's Note

Springer Nature remains neutral with regard to jurisdictional claims in published maps and institutional affiliations.

Submit your manuscript to a SpringerOpen<sup>®</sup> journal and benefit from:

- Convenient online submission
- Rigorous peer review
- Open access: articles freely available online
- High visibility within the field
- Retaining the copyright to your article

Submit your next manuscript at ► [springeropen.com](https://www.springeropen.com)